

ORIGINAL ARTICLE

The Effect of Banana (*Musa nana* Lour.) Peel Extract and Omega-3 on Biochemical and Histopathological Characteristics in Rat Model of Polycystic Ovary Syndrome

Jamal Yazdani¹, Mohammad-Jafar Dehzad¹, Mohammad Mehdi Ommati^{2,3}, Reza Heidari³, Mohammad Reza Arabnezhad⁴, Najmeh Hejazi^{5*}, Afsane Ahmadi⁵

1. Department of Clinical Nutrition, School of Nutrition and Food Sciences, Shiraz University of Medical Sciences, Shiraz, Iran
2. Henan Key Laboratory of Environmental and Animal Product Safety, College of Animal Science and Technology, Henan University of Science and Technology, Luoyang 471000, Henan, China
3. Pharmaceutical Sciences Research Center, Shiraz University of Medical Sciences, Shiraz, Iran
4. Department of Toxicology and Pharmacology, School of Pharmacy, Kerman University of Medical Sciences, Kerman, Iran
5. Nutrition Research Center, Department of Clinical Nutrition, School of Nutrition and Food Sciences, Shiraz University of Medical Sciences, Shiraz, Iran

ARTICLE INFO

Keywords:

Banana
Omega 3
Polycystic ovary syndrome
Histopathology
Insulin resistance

*Corresponding author:

Najmeh Hejazi, PhD;
Nutrition Research Center,
Department of Clinical Nutrition,
School of Nutrition and Food
Sciences, Shiraz University of
Medical Sciences, Shiraz, Iran.
Tel: +98-9177020859
Email: najmehhejazi@gmail.com
nhejazi@sums.ac.ir

Received: August 18, 2024

Revised: November 11, 2024

Accepted: November 20, 2024

ABSTRACT

Background: In women of reproductive age, polycystic ovary syndrome (PCOS) is a prevalent endocrine condition. This study assessed the effect of banana (*Musa nana* Lour.) peel extract and omega-3 on biochemical and histopathological features in rat model of PCOS.

Methods: After PCOS induction, 56 adult female rats were randomly divided into seven groups. In group 1, healthy rats were given 20 mg/kg/day of normal saline. Group 2 comprised PCOS rats receiving saline as 20 mg/kg/day. Group 3 included rats with PCOS receiving 240 mg/kg/day omega-3. Group 4 consisted of rats with PCOS receiving 6 mL/kg/day of banana peel extract. Group 5 contained rats with PCOS receiving 12 mL/kg/day banana peel extract. Group 6 enrolled rats with PCOS taking 240 mg/kg/day omega-3 and 12 mL/kg/day banana peel extract. Group 7 consisted of rats with PCOS treated with 200 mg/kg/day metformin. Serum biochemical parameters and ovarian oxidative stress were evaluated together with histological assessment. The duration of treatment for all groups was 8 weeks.

Results: Glycemic indices, serum triglyceride level, serum testosterone concentration, oxidative stress, and body weight significantly decreased. The ovarian tissue pathology in the animals treated with banana peel extract and omega-3 in comparison to the PCOS control group showed an improvement ($p < 0.05$).

Conclusion: Omega-3 supplementation with banana peel extract as an antioxidant may have beneficial effects on biochemical parameters and pathological demonstrations of PCOS.

Please cite this article as: Yazdani J, Dehzad MJ, Ommati MM, Heidari R, Arabnezhad MR, Hejazi N, Ahmadi A. The Effect of Banana (*Musa nana* Lour.) Peel Extract and Omega-3 on Biochemical and Histopathological Characteristics in Rat Model of Polycystic Ovary Syndrome. Int J Nutr Sci. 2025;10(1):81-91. doi: 10.30476/ijns.2025.101331.1297.

Introduction

In women of reproductive age, polycystic ovary syndrome (PCOS) is a prevalent endocrine condition, which is recognized by anovulation/oligo-ovulation, hyperandrogenism, and the appearance of polycystic ovaries (pearl grooves) (1). Previous studies showed obesity and overweight in more than 50% of patients with PCOS. An increased serum testosterone level (hyperandrogenism) has also been observed in almost 70% of these patients (2, 3). In addition, this syndrome is associated with symptoms such as amenorrhea, hirsutism, inflammation, dyslipidemia, and insulin resistance, which increase the risk of cardiovascular diseases and diabetes in patients (4). Although the primary etiology of PCOS is not known, secondary hyperandrogenism and insulin resistance have been mentioned as possible causes (4). The primary treatment approach for controlling PCOS has been identified as lifestyle adjustment, including weight loss and increased physical exercise. Yet, some studies have defended antiandrogen and insulin sensitizer compounds (5). Considering the adverse effects of synthetic drugs, they have been recommended to be substituted by available dietary sources (4, 6).

Omega-3 fatty acids have anti-obesity, anti-inflammatory, and anti-insulin resistance effects. However, some studies showed conflicting results regarding their impact on serum testosterone levels and the plasma androgen profile in patients with PCOS (7, 8). Omega-3 fatty acids are susceptible to oxidation, because of binary bonds in their chemical structures. On the other hand, insulin resistance-dependent oxidative stress exists in PCOS patients as the leading cause of secondary complications. Therefore, using antioxidants with omega-3 supplements may have preventative effects (9, 10). The combined effects of omega-3 and antioxidants have recently been highlighted, as some studies have demonstrated that these two substances' combined impact was more robust than their individual effects. This has been studied in patients with depression and liver disorders, and the results have revealed the beneficial effects of fortified omega-3 with antioxidants (11, 12).

Bananas are rich in antioxidants. Interestingly, the highest concentration of antioxidant compounds is found in the often-discarded banana peel. Notable antioxidants in banana peel include catechin, epicatechin, gallic acid, epigallocatechin, and catecholamines (polyphenols), along with carotenoids. Additionally, banana peels provide essential nutrients such as potassium, protein, fiber, and vital amino acids (10). Some studies have shown

the hypoandrogenic effects of polyphenols. Therefore, as an antiandrogen agent, it may be effective in managing patients with PCOS (13, 14). As far as we know, no research has examined the effectiveness of banana peel antioxidants in combination with omega-3 in PCOS patients. Thus, the present study investigated the impact of banana peel extract, as food waste, alongside eicosapentaenoic acid (EPA) and docosahexaenoic acid (DHA) on glycemic indices, lipid profile, testosterone level, and oxidative stress indicators in rats with PCOS's ovarian tissue. The study also aimed to evaluate the histopathology of ovaries after the intervention.

Materials and Methods

The Laboratory Animal Breeding Center, Shiraz University of Medical Sciences, Shiraz, Iran, provided female Sprague-Dawley rats (n=56, 10-12 weeks old). The rats were housed in an environment with a 12-hour light/dark cycle, relative humidity of 55±5%, and a temperature of 22±1°C. During all experiments, rats had unrestricted access to standard rat chow meal (Behparvar®, Tehran, Iran) and tap water. All operations involving laboratory animals complied with the Shiraz University of Medical Sciences Ethics Committee's standards for the care and use of laboratory animals. The Ethics Committee of Shiraz University of Medical Sciences, Shiraz, Iran, approved the guidelines for the care and use of laboratory animals, and all operations involving those animals were carried out in compliance with those rules (96-01-84-16011). Additionally, all techniques are documented in compliance with the ARRIVE standards for the reporting of animal research. The techniques used with the plant sample (banana) were also carried out in compliance with the applicable guidelines and regulations.

Determining the estrus cycle was accomplished by monitoring cells in the vaginal smear cells to ensure appropriate timing for PCOS induction using tetrazole (15). PCOS was then induced in all the experimental rats, except the control group, for 21 consecutive days using letrozole (Aburaihan Pharma Co., Tehran, Iran) dissolved in normal saline. Vaginal smears from letrozole-treated rats indicate a significantly high accumulation of leukocytes and few keratinocytes (Giemsa staining) (16). From the first day of the study, the rats received 1.1 mg/kg of letrozole orally per day. In the control group, 2 mL of normal saline was administered orally per day from the first day of the study for 21 days (17). Subsequently, the collected vaginal smears were evaluated by a microscope to confirm the PCOS induction in the rats.

The banana peel (*Musa nana* Lour.) extract by use of water, ethyl acetate, ethanol, and methanol to target a broad range of bioactive compounds was purchased from Ebne Masouyeh Pharmaceutical Company (Tehran, Iran). The omega-3 supplement was acquired from the Zahravi Company (Tabriz, Iran), which offers a standardized formulation with 180 mg of EPA and 120 mg of DHA per gram. Before the PCOS induction, the random allocation of the 56 rats into seven trial groups was achieved through a process of random selection. Rats were in a uniform shape and body weight and underwent a one-week adaptation period. Subsequently, the allocation process involved assigning each animal a numerical identifier and placing these identifiers on tag papers. These papers were then mixed and randomly selected from a basket to determine the assignment of each rat to a specific trial group. This method ensured that the allocation process was both accidental and random, thereby minimizing bias and ensuring an unbiased distribution of animals across the different experimental groups. The optimal dosage and intervention time exhibited variability across studies. In our case, we have determined our dosage and timing based on insights gleaned from previous researches (18-20).

The treatments were as follows: Group 1 as control rats without PCOS received 1 mL/day of normal saline (sodium chloride 0.9% w:v) by gavage for eight weeks. Group 2 as PCOS control group (letrozole) received 1 mL/day of normal saline orally for eight weeks. Group 3 was rats with PCOS that received 240 mg/kg/day of omega-3 (43.2 mg EPA and 28.8 mg DHA) by gavage for eight weeks. Group 4 was rats with PCOS that received 6 mL/kg/day of banana peel extract by gavage for eight weeks. Group 5 was rats with PCOS that received 12 mL/kg/day of banana peel extract by gavage for eight weeks. Group 6 was rats with PCOS that received 240 mg/kg of omega-3 and 12 mL/kg of banana peel extract/day by gavage for eight weeks. Group 7 was rats with PCOS that received 200 mg/kg/day of metformin (Aburaihan Pharma Co., Tehran, Iran) by gavage for eight weeks.

From the beginning through the completion of the trial, the rats' body weight was checked weekly. Before taking blood and ovarian samples, the rats received an intraperitoneal dosage of thiopental (80 mg/kg, i.p.) at the end of the trial (24 hours after the final gavage). Blood samples were collected from the abdominal vena cava and used to prepare the serum by centrifugation (3000 g/min for 10 minutes). All serum samples were stored at -80°C until biochemical analysis. The sera were used to evaluate glucose, insulin, testosterone, and lipid profile levels.

The glucose serum level was determined utilizing an enzymatic colorimetric approach via a biochemical autoanalyzer device (BT-1500, Italy) utilizing a Pars Azmoon Co. diagnostic kit (ParsAzmoon™, Tehran, Iran) following the guidelines provided by the manufacturer (21). The serum insulin concentration was measured using an ELISA kit (Bioassay technology laboratory, Cat No. E1163Mo). Insulin resistance was measured using HOMA-IR, or Homeostatic Model Assessment: $\text{HOMA-IR} = \text{fasting insulin } (\mu\text{U/mL}) \times \text{fasting glucose (mg/dL)} / 405$ (14).

The serum testosterone level was also measured using ELISA kits (Bioassay technology laboratory, Cat No. E0260Mo). A biochemical auto-analyzer device (BT-1500, Italy) using Pars Azmoon Co. enzyme kits was used to assay the serum concentrations of lipid profiles, including total cholesterol (TC), high-density lipoprotein cholesterol (HDL-C), low-density lipoprotein cholesterol (LDL-C), and triglycerides (TG), using an enzymatic colorimetric method. The ovarian tissue was stored in 10% neutral buffered formalin. Hematoxylin and eosin (H&E) were used to stain the formalin-fixed tissue, which was subsequently embedded in paraffin and cut into 5-micrometer slices. Finally, tissue slides were used for histological analysis under light microscopy.

A total of 200 mg of ovary samples were homogenized in 2 mL of ice-cooled, Tris-HCl buffer (40 mM, pH=7.4, 4°C, 1:10 w/v). Following that, 100 μL of the tissue homogenate was combined with one milliliter of the Tris-HCl buffer (40 mM, pH=7.4) and 10 μL of 2', 7' dichlorofluorescein diacetate (final concentration=10 μM) (22). After that, the mixture was incubated for 15 minutes in the dark at 37°C. Finally, a multipurpose microplate reader of FLUOstar Omega® (BMG Labtech, Germany) was used to measure the samples' fluorescence intensity (λ excitation=485 nm and λ emission=525 nm) (23, 24).

Thiobarbituric acid reactive substances (TBARs) were analyzed in the ovarian tissue as a marker of lipid peroxidation (25). Briefly, 1 mL of the ovarian tissue homogenate (10 percent w/v in ice-cooled KCl, 1.15% w: v, 4°C) was added to a reaction mixture consisting of TBA (0.375 percent w:v in double-distilled water), TCA (15 percent w:v in double-distilled water), and hydrochloric acid (2 N) (pH=2). The samples were heated for 45 minutes in a water bath at 100 degrees Celsius after being vortexed for 5 minutes (26). Then, 2 mL of n-butanol was added, and the mixture was vortexed for 5 minutes. The samples were centrifuged (10,000 g, 10 min), and a plate reader (Epoch, Bio-Tek® Instruments, Highland Park, USA) was used to measure the absorbance of the produced color in the n-butanol phase at a wavelength of 532 nm (27).

The Ferric Reducing Antioxidant Power (FRAP) assay for the ovary evaluated the generation of a blue-colored Fe^{2+} -tripyridyltriazine complex from the colorless oxidized Fe^{3+} form with the assistance of electron-donating antioxidants (28, 29). The FRAP working solution utilized in the present study was prepared by combining 1 part ferric chloride (FeCl_3 , 20 mmol/L in deionized water), 1 part Fe^{3+} -2,4,6-tripyridyl-s-triazine (TPTZ) (10 mmol/L in 40 mmol/L hydrochloric acid), and 10 parts acetate buffer (300 mmol/L, pH=3.6). Then, 1.5 mL of the FRAP working solution, 50 μL of the tissue homogenate (10 percent w:v in ice-cooled KCl, 1.15% w:v, 4°C), and 150 μL of deionized water were combined. The reaction mixture was then incubated for 5 minutes at 37°C in the dark. After that, the samples were centrifuged, and an EPOCH plate reader (Bio-Tek® Instruments, Highland Park, USA) was used to measure the absorbance of the color produced (30).

The following items were bought from Sigma (Sigma-Aldrich, St. Louis, MO): TPTZ, ferric chloride hexahydrate ($\text{FeCl}_3 \cdot 6\text{H}_2\text{O}$), thiobarbituric acid (TBA), sucrose, and trichloroacetic acid (TCA). All salts used to make buffer solutions, including 3-diol-hydrochloride (Tris-HCl), were of analytical quality and purchased from Merck (Darmstadt, Germany). SPSS software (version 22.0, Chicago, IL, USA) was used for all statistical analyses.

The Kolmogorov-Smirnov test was conducted to determine if the data were normally distributed. The data were presented as mean and standard deviation (SD). One-way Analysis of Variance (ANOVA) with the Tukey test as the post-hoc test was used to compare the research groups. Statistics were judged significant at $p \leq 0.05$.

Results

Table 1 demonstrate a substantial difference in blood glucose, insulin, and HOMA-IR between the seven research groups ($p < 0.001$). Also, the blood concentrations of glucose, insulin, and HOMA-IR in the PCOS control group were noticeably more significant than those in the control group ($p < 0.001$). However, the results demonstrated a considerable decrease in insulin concentrations, blood sugar, and HOMA-IR in the groups treated with metformin, omega-3, banana peel extract, and the combination group. Based on the results in Table 1, regarding TG serum level, the PCOS control and control group had a noticeable difference ($p = 0.041$). The combination of banana peel extract and omega-3 was the best treatment, like metformin, that significantly reduced the serum level of TG when compared to the PCOS control group ($p = 0.001$ and $p = 0.005$, respectively). However, other serum lipids like LDL-C, HDL-C, and TC did not notably differ between the PCOS and control groups (Table 1).

Table 1: Weight, glycemic indices, and lipid profile of the rats under different treatments

Groups Variables	Control (n=8)	PCOS control (n=8)	PCOS + metformin (n=8)	PCOS + omega-3 (n=8)	PCOS + BP extract(6 m) (n=8)	PCOS + BP extract (12 mg) (n=8)	PCOS + BP extract (12 mg) + omega-3 (n=8)	P value
Insulin (mIU/L)	2.08±0.46	3±0.26 ^a	2.16±0.19 ^b	1.98±0.24 ^b	2.35±0.24 ^b	2.51±0.18 ^{bc}	2.65±0.19 ^{bc}	≤0.001
Glucose (mg/dl)	95.12±3.83	164.75±2.37 ^a	122.87±2.03 ^b	128.37±6.47 ^{bc}	140.12±2.23 ^{bc}	125.5±3.58 ^b	116.87±3.35 ^{bc}	≤0.001
HOMA-IR	0.49±0.11	1.22±0.1 ^a	0.65±0.05 ^b	0.63±0.08 ^b	0.81±0.09 ^{bc}	0.77±0.06 ^{bc}	0.76±0.04 ^{bc}	≤0.001
TG (mg/dl)	54.25±17.45	78.75±41.02 ^a	37.75±8.22 ^b	44.87±19.26 ^b	70.75±19.81 ^c	72.12±30.35 ^c	39.12±7.98 ^b	0.002
LDL-C (mg/dl)	13.37±2.26	13.87±3.18	14.25±4.06	18.25±2.91 ^c	16.37±3.15	12.25±2.43	13.87±3.39	0.007
HDL-C (mg/dl)	27.87±9.12	20.75±9.96	36.25±7.81 ^{ab}	29.37±7.00 ^b	19.42±5.66 ^c	22.12±5.46 ^c	28.25±6.75 ^c	0.001
T-Chol (mg/dl)	45.00±13.74	50.12±9.23	58.87±10.68	55.87±11.28	48.87±7.77	45.25±8.97	52.00±7.46	0.069
Testosterone (nmol/L)	37.43±1.85	48.77±2.99 ^a	40.02±2.19 ^b	37.82±2.88 ^{bc}	36.62±2.10 ^{bc}	40.12±1.59 ^b	37.86±1.26 ^{bc}	≤0.001
Weight (gr)	193.59±4.91	248.06±10.74 ^a	219.85±23.75 ^b	220.32±19.41 ^b	227.65±10.62 ^b	227.96±12.95 ^b	222.09±15.42 ^b	≤0.001

Data have been presented as mean±SD (n=56); $P < 0.05$ was considered significant. ^aIndicates a significant difference compared to the control group; ^b indicates a significant difference compared to the PCOS control group; ^c indicates a significant difference compared to the metformin group. TG, triglyceride; T-Chol, total Cholesterol; LDL, low-density lipoprotein; HDL, high-density lipoprotein; HOMA-IR, homeostatic model assessment insulin resistance.

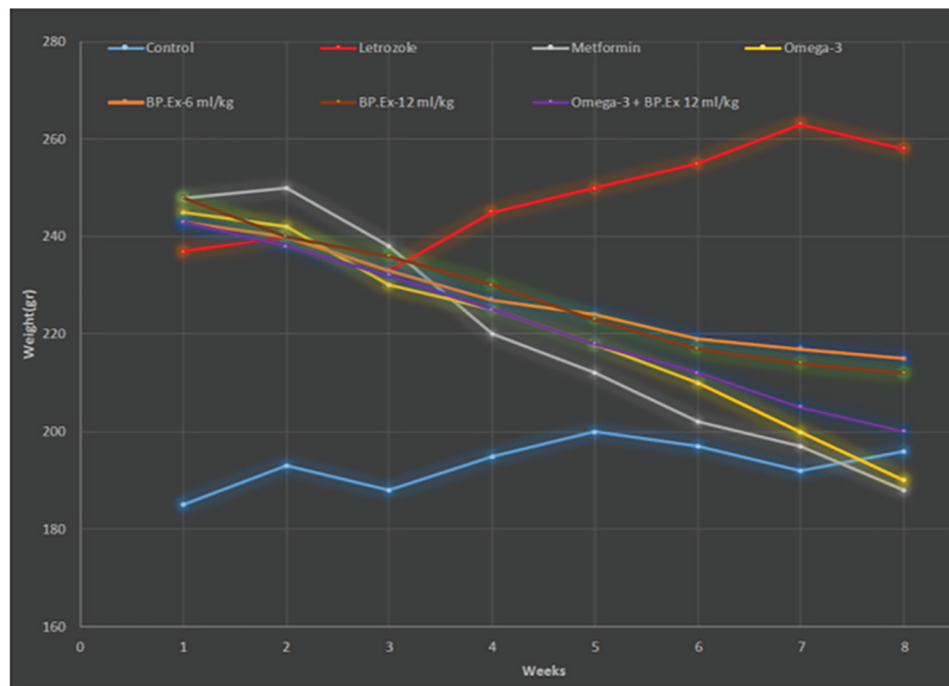


Figure 1: Weight changes among the rats in different treatment groups during the study.

Table 2: Oxidative stress parameters in the ovarian tissues of the rats under different treatments

Groups Variables	Control (n=8)	PCOS control (n=8)	PCOS + metformin (n=8)	PCOS + omega-3 (n=8)	PCOS + BP extract (6 mg) (n=8)	PCOS + BP extract (12 mg) (n=8)	PCOS + BP extract (12 mg) + omega-3 (n=8)	P-value
ROS level (DCF fluorescent intensity)	27156.25±1512.56	186602.1±2212.16 ^{ac}	6520.5±1217.21 ^b	83255.13±999.38 ^{bc}	114528±3143.62 ^{bc}	114528±3143.62 ^{bc}	44399±2522.15 ^{bc}	≤0.001
TAC (FRAP assay, % control)	120.58±1.19	60.46±1.23 ^{ac}	148.08±2.37 ^b	110.78±0.78 ^{bc}	75.46±1.38 ^{bc}	99.56±1.66 ^{bc}	149.98±7.64 ^b	≤0.001
LPO (nmol of TBARS/mg protein)	0.22±0.01	0.42±0.01 ^{ac}	0.23±0.01 ^b	0.21±0.01 ^{bc}	0.28±0.007 ^{bc}	0.24±0.01 ^b	0.22±0.01 ^b	≤0.001

Data have been presented as mean±SD (n=56); $P < 0.05$ was considered significant. ^aIndicates significant difference compared to the control group; ^b indicates a significant difference compared to the PCOS control group; ^c indicates significant difference compared to the metformin group. ROS, reactive oxygen species; TAC, total antioxidant capacity; LPO, lipid peroxidation

In terms of the blood level of testosterone, the results revealed a substantial difference between the control group and the PCOS control group (Table 1) ($p < 0.001$). Moreover, omega-3, banana peel extract, and omega-3 combination therapy significantly lowered the testosterone serum level compared to the PCOS control group ($p < 0.001$). The results demonstrated that treatment with omega-3, banana peel extract, and combination therapy significantly reduced testosterone levels compared to metformin treatment. As Figure 1 depicts, letrozole induction significantly increased the rats' weight ($p < 0.001$). Table 1 displays the weights of the rats at the end of the study. Regarding animal weight, the findings showed a substantial difference between the seven groups ($p < 0.001$). The results of the LSD post-hoc analysis revealed that the rats in the PCOS

control group weighed more than the control group ($p < 0.001$). However, treatment with omega-3, banana peel extract, and combination therapy significantly decelerated the weight increment against the PCOS control group ($p < 0.001$).

The findings showed that the PCOS control group's ovarian tissues' reactive oxygen species (ROS) levels were noticeably higher than in the control group, and their antioxidant capacity (FRAP) was lower ($p < 0.001$) (Table 2). Additionally, the outcomes showed a noteworthy difference in ROS and the degree of FRAP in ovarian tissues between all treatment groups and the PCOS control group (Table 2). The combination of banana peel extract and omega-3 was highly effective in reducing ROS in the ovarian tissue, even more effective than metformin ($p < 0.001$).

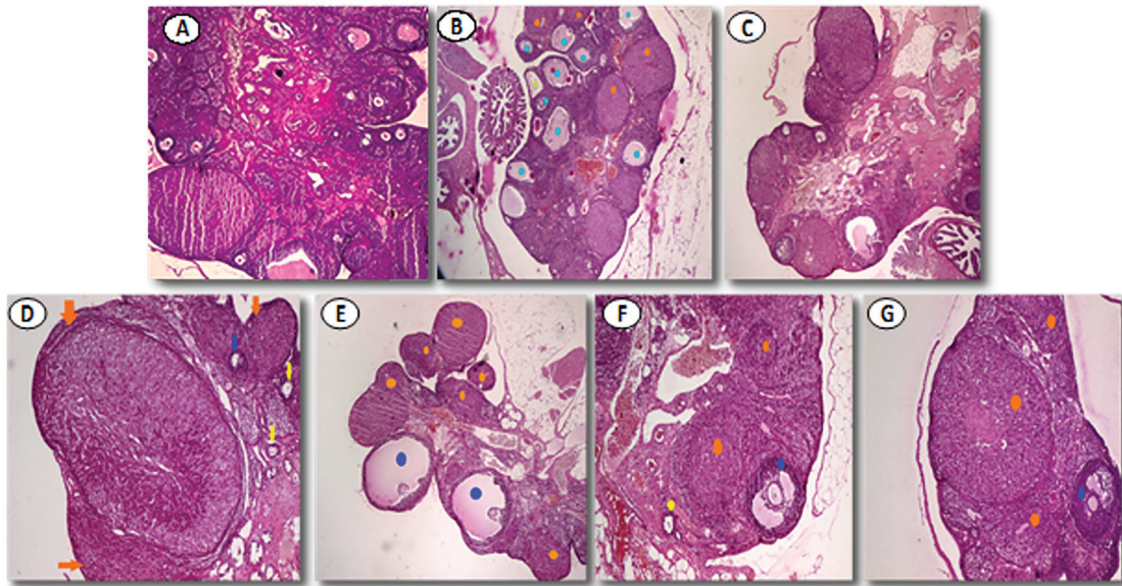


Figure 2: Histopathologic changes in the ovarian tissues of the rats in different treatment groups. A: Control rats without PCOS received 1 mL/day of normal saline, B: PCOS control group (letrozole) receiving 1 mL/day of normal saline, C: Rats with PCOS received 240 mg/kg/day of omega-3, D: Rats with PCOS received 6 mL/kg/day of banana peel extract, E: Rats with PCOS received 12 mL/kg/day of banana peel extract, F: Rats with PCOS received 240 mg/kg omega-3 and 12 mL/kg banana peel extract/day, G: Rats with PCOS received 200 mg/kg/day of metformin, Yellow: preantral follicle; Blue: antral follicle; Green: cystic follicle; Orange: corpus luteum.

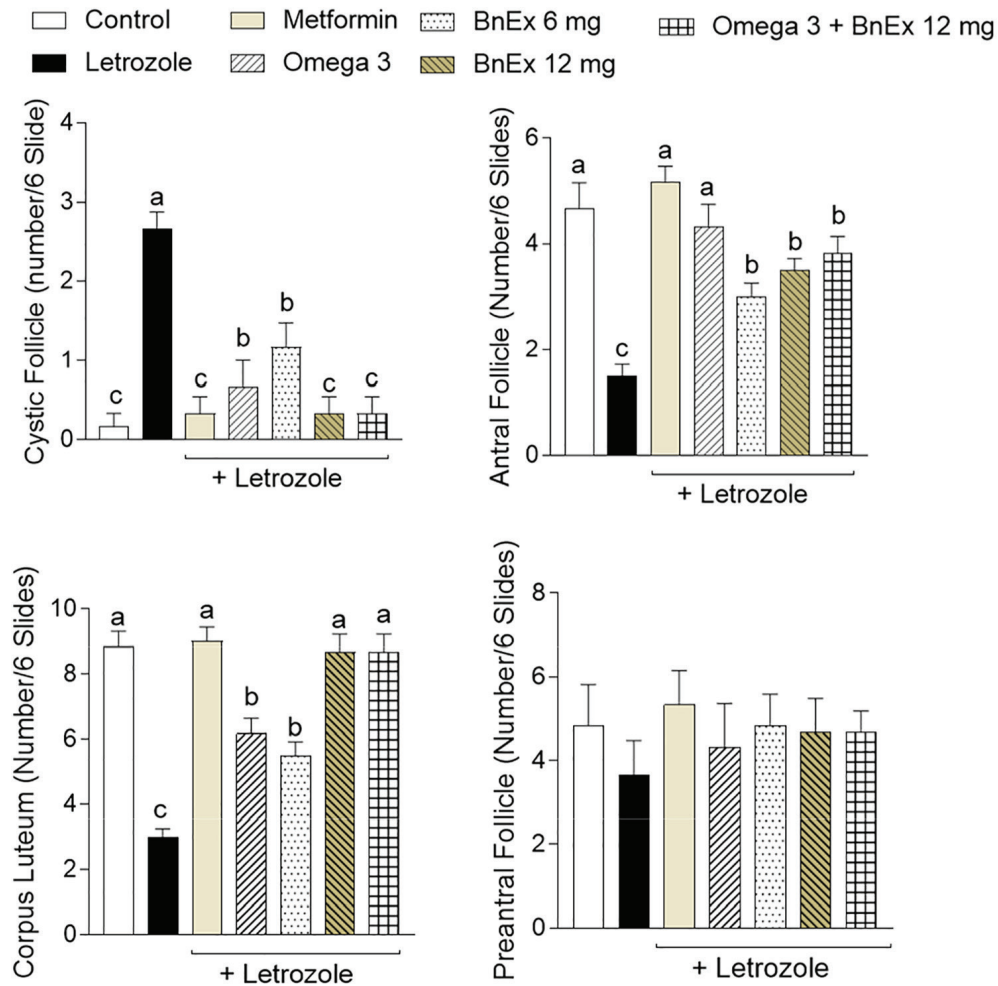


Figure 3: The scores of ovarian histopathological alterations in the letrozole model of PCOS. BnEx, banana extract. Data are given as Mean±SD (n=56). Columns with different alphabetical superscripts are statistically different ($p<0.05$)

Similar to metformin, the combination treatment was also influential in the FRAP of the ovarian tissue ($p<0.001$) in comparison to the PCOS control group (Table 2).

The levels of lipid peroxidation (LPO) in the ovarian tissues have been presented in Table 2. Accordingly, the LPO level increased in the PCOS control rats compared to the control group ($p<0.05$). It decreased in all treatment groups compared to the PCOS control group ($p<0.05$).

Main histopathological alterations in PCOS rats included a decrease in corpus luteum, antral, and preantral follicles along with a significant increase in cystic follicles (Figure 3). Figure 2 and Figure 3 show that the weight and volume of the ovaries and cyst volumes significantly increased. In contrast, the volume and number of corpora lutea decreased considerably in the PCOS control group compared to the control group ($p=0.001$, $p<0.001$, and $p=0.023$, respectively). The results also indicated a significant reduction in ovarian tissue injury in all treatment groups compared to the PCOS control group. In this regard, the highest dose of banana peel extract and omega-3 therapy was found to be the most effective when administered together ($p<0.001$).

Discussion

The current study was designed to evaluate the effects of banana peel extract, as an antioxidant, combined with omega-3 in comparison to metformin on biochemical and pathological indices in rats with letrozole-induced PCOS. Previous studies demonstrated that PCOS induction via letrozole in animals produced biochemical and pathological symptoms similar to human PCOS (17). The current study showed that administering banana peel extract and omega-3 supplements orally for eight weeks could improve serum biochemical parameters such as fasting blood glucose, TG, insulin resistance, and testosterone levels. It also significantly enhanced the ovarian tissues' oxidative stress levels and pathological factors compared to the PCOS control group. Furthermore, the combination of banana peel extract, omega-3, and metformin significantly reduced fasting blood glucose level compared to the PCOS control group. In addition, the level of insulin resistance noticeably decreased in all intervention groups when compared to the PCOS control group, with omega-3 showing the most considerable effect. These data indicated that banana peel extract could be used as a source of active ingredients to manage PCOS complications with minimum adverse effects.

According to a previous study, banana peel extract has polyphenolic compounds such as catechin,

epicatechin, gallic acid, galloocatechin, epigallocatechin, catecholamines, and other antioxidants such as carotenoids. Antioxidants may have positive effects on improving glycemic indices. In addition, antioxidants can potentially inhibit the activity and production of free radicals in various ways, like binding to metals, preventing them from oxidation, and scavenging free radicals (10). Polyphenolic and antioxidant compounds can also increase glucose uptake, insulin secretion, insulin sensitivity, and Glucagon Like Peptide-1 (GLP-1) that reduces hyperglycemia (10). On the other hand, omega-3 fatty acids in mammals can be precursors to the synthesis of anti-inflammatory compounds such as Leukotrienes (LBT5), Prostaglandins (PG3), and Thromboxane (TXA3), thereby reducing inflammation, oxidative stress, and cellular damage. These can eventually improve insulin resistance and blood glucose levels (7, 8).

In line with other studies, compared with the control group, the study findings revealed a considerable rise in ROS levels and LPO activity and a marked reduction in the FRAP of the ovarian tissues in the PCOS control rats (31). All these factors have been reported to play a crucial part in oxidative stress and its complications related to PCOS (31). In the present study, banana peel extract and omega-3 had a synergistic effect on decreasing ROS level and increasing FRAP level in the ovarian tissues that is significantly different from the individual effect of banana peel extract and omega-3. It was even found to be more effective than metformin alone. The LPO level of the ovarian tissue also significantly declined by using combination therapy with banana peel extract and omega-3 when compared to the PCOS control group. As mentioned earlier, as an antioxidant, banana peel extract reduces cellular oxidative stress (10). Other mechanisms of action for antioxidants include increasing the activity of enzymes such as Glutathione Peroxidase (GPX), Super Oxide Dismutase (SOD), Thioredoxin Reductase (TR), and Catalase (CAT) which all have a significant impact on improving oxidative stress and, consequently, glycemic indices (9). Moreover, omega-3 fatty acids can affect the morphology, dynamics, and function of mitochondria, which improve cellular respiratory function, increase ATP production, improve cell metabolism, and reduce fat accumulation, ultimately decreasing oxidative stress and insulin resistance (13).

Hyperlipidemia and overweight may be other symptoms and complications associated with PCOS. In a study by Skarra *et al.*, rats with letrozole-induced PCOS and the control group showed a substantial difference in elevated TG, LDL, TC, and HDL

level and body weight (32). In the current study, however, only TG level and body weight significantly increased against the control group. This could be caused by the shorter duration of PCOS induction in this study than in the one performed by Skarra *et al.* In the present research, when compared to the PCOS control group, ingestion of omega-3 both on its own and in combination with banana peel extract significantly reduced TG level, whereas the groups treated with banana peel extract alone (low and high doses) showed no noticeable difference from the PCOS control group. Therefore, omega-3 fatty acids were the main reason for reducing TG serum levels.

The current study results indicated a notable decrease in the body weight of the rats with PCOS in the combination group and the group treated with omega-3 alone compared with the PCOS control group at the end of the study (after eight weeks). One of the possible mechanisms that can be considered for the effect of omega-3 fatty acids on the reduction of TG level and body weight can be the increase in fatty acid oxidation activity resulting from improved mitochondrial function and increased mitochondrial CPT-1 activity (23). The result is a marked improvement in the lipolysis process. Omega-3 fatty acids can also increase Peroxisome proliferator-activated receptor alpha (PPAR- α) activity, and ultimately increase fatty acid oxidation by producing anti-inflammatory eicosanoids (33). Additionally, previous investigations have shown that omega-3 fatty acids might lessen the SREBP-1 gene's expression, eventually leading to less TG production (34). Moreover, omega-3 fatty acids and antioxidants such as polyphenolic and carotenoid compounds can increase adiponectin levels and decrease leptin, resistin, and inflammatory markers such as IL-6, Monocyte Chemoattractant Protein-1 (MCP-1), and Tumor necrosis factor (TNF). The decline of inflammation and macrophages in the adipose tissue and increment of lipolysis and fatty acid oxidation simultaneously with a decrement of lipogenesis may result in bodyweight reduction (35).

Elevated level of testosterone is one of the essential symptoms of PCOS. In agreement with another study, our findings showed a markable increase in the blood level of testosterone in the animals with letrozole-induced PCOS compared to the control group (36). However, consumption of banana peel extract, omega-3, and combination therapy significantly decreased testosterone level compared to the PCOS control group. These findings can be justified by the positive effect of banana peel extract and omega-3 fatty acids on improving glycemic indices and insulin resistance. Additionally, earlier investigations have revealed that

insulin resistance may be a significant contributor to changes in levels of hormones such as androgens among patients with PCOS (37, 38).

The findings of the earlier research, as well as the present one, indicated that damage to the ovarian tissue and multiple cysts in this tissue led to a decrease in ovulation and the chance of fertility in rats with PCOS (39, 40). The findings also revealed a significant decline in ovarian tissue injury, including a decrease in the number of cystic follicles, a drop in the number of atresia follicles, and an increase in the number of corpora lutea by using the combination of banana peel extract and omega-3. Omega-3 showed similar effects to metformin compared to the PCOS control group. Other study findings, including the positive effect of these compounds on the improvement of insulin resistance, androgens, and oxidative stress can justify these findings. It should be mentioned that current pharmacotherapeutic strategies against PCOS aim to reduce the prevalence of cystic follicles in the ovary. However, our finding indicates that using agents such as banana peel extract not only significantly decreased the number of cystic follicles, but also enhanced serum biochemical parameters (*e.g.*, TG and glucose levels), and blunted complications such as oxidative stress in the ovary tissue. Overall, the current study results demonstrated that omega-3 and banana peel extract could be used to treat PCOS. Therefore, human studies have to be conducted on the issue. In addition, further studies are recommended to measure the androgenic profile. One of this study's drawbacks was the inability to identify the components of the banana peel extract.

Conclusion

The findings of this investigation showed that the oral administration of higher doses of banana peel extract combined with omega-3 fatty acids was more effective compared to their single administrations and might have positive effects on the improvement of the clinical and biochemical complications associated with PCOS including increased glycemic indices, hypertriglyceridemia, hyperandrogenemia, oxidative stress, and body weight changes. Combining these two compounds also improved the histopathological parameters of the ovarian tissue. Therefore, it seems that omega-3 and banana peel extract may have a role in alleviating PCOS complications as supplementary agents. Further studies are needed to determine the precise cellular and molecular mechanism(s) of this effect and the clinical application of these agents. It should also be mentioned that in the current study, no side effect of the investigated extract was

detected as evidenced by no significant changes in blood biochemistry of extract-treated rats. Clearly, more investigation (e.g., with a higher dose of this product or in a longer time) could enhance our understanding of the mechanism of action of this preparation and finally identification of its active ingredients for further preclinical/clinical research.

Acknowledgement

This article was a part of the thesis written by J. Y., which was financially supported (grant No. 96-01-84-16011) by the Research Vice-chancellor of Shiraz University of Medical Sciences, Shiraz, I.R. Iran. Hereby, the authors would like to thank Ms. A. Keivanshekouh at the Research Consultation Center (RCC) of Shiraz University of Medical Sciences for her invaluable assistance in improving the use of English in the manuscript.

Funding

This article was financially supported (grant No. 96-01-84-16011) by the Research Vice-chancellor of Shiraz University of Medical Sciences. This was an internal research grant from Shiraz University of Medical Sciences for student thesis process including Laboratory works, kits, and animal lab.

Authors' Contribution

JY: Investigation, Visualization, Software, Writing the Original Draft, Data Curation. MjD: Resources, Software, Writing the Original Draft, Reviewed and approved the manuscript. RH: Resources, Methodology, Writing, Review and Editing. NH: Conceptualization, Methodology, Project Administration, Writing, Review and Editing, Supervision. MmO: investigation, Visualization, Software, Reviewed and approved the manuscript. MrA: investigation, Visualization, Software, Reviewed and approved the manuscript. AA: Conceptualization, Methodology, Reviewed and approved the manuscript

Conflict of Interest

None declared.

References

- 1 Sirmans SM, Pate KA. Epidemiology, diagnosis, and management of polycystic ovary syndrome. *Clin Epidemiol.* 2014;6:1-13. DOI: 10.2147/CLEP.S37559. PMID: 24379699.
- 2 Tehrani FR, Simbar M, Tohidi M, et al. The prevalence of polycystic ovary syndrome in a community sample of Iranian population: Iranian PCOS prevalence study. *Reprod Biol Endocrinol.* 2011;9:39. DOI: 10.1186/1477-7827-9-39. PMID: 21435276.
- 3 Tehrani FR, Rashidi H, Azizi F. The prevalence of idiopathic hirsutism and polycystic ovary syndrome in the Tehran Lipid and Glucose Study. *Reprod Biol Endocrinol.* 2011;9:144. DOI: 10.1186/1477-7827-9-144. PMID: 22044512.
- 4 Orio F, Palomba S. Reproductive endocrinology: new guidelines for the diagnosis and treatment of PCOS. *Nat Rev Endocrinol.* 2014;10:130-2. DOI: 10.1038/nrendo.2013.248. PMID: 24322653.
- 5 Escobar Morreale HF. Polycystic ovary syndrome: treatment strategies and management. *Expert Opin Pharmacother.* 2008;9:2995-3008. DOI: 10.1517/14656560802559932. PMID: 19013863.
- 6 Taylor AE. Insulin-lowering medications in polycystic ovary syndrome. *Obstet Gynecol Clin North Am.* 2000;27:583-95. DOI: 10.1016/s0889-8545(05)70157-1. PMID: 10958005.
- 7 Gray B, Steyn F, Davies P, et al. Omega-3 fatty acids: a review of the effects on adiponectin and leptin and potential implications for obesity management. *Eur J Clin Nutr.* 2013;67:1234-42. DOI: 10.1038/ejcn.2013.197. PMID: 24129365.
- 8 Sadeghi A, Djafarian K, Mohammadi H, et al. Effect of omega-3 fatty acids supplementation on insulin resistance in women with polycystic ovary syndrome: Meta-analysis of randomized controlled trials. *Diabetes Metab Syndr.* 2017;11:157-62. DOI: 10.1016/j.dsx.2016.06.025. PMID: 27484441.
- 9 Ortiz L, Dorta E, Lobo MG, et al. Use of banana (*Musa acuminata* Colla AAA) peel extract as an antioxidant source in orange juices. *Plant Foods Hum Nutr.* 2017;72:60-6. DOI: 10.1007/s11130-016-0591-0. PMID: 27987069.
- 10 Rebello LPG, Ramos AM, Pertuzatti PB, et al. Flour of banana (*Musa* AAA) peel as a source of antioxidant phenolic compounds. *Food Res Int.* 2014;55:397-403. DOI: 10.1016/j.foodres.2013.11.039.
- 11 Méndez L, Ciordia S, Fernández MS, et al. Changes in liver proteins of rats fed standard and high-fat and sucrose diets induced by fish omega-3 PUFAs and their combination with grape polyphenols according to quantitative proteomics. *J Nutr Biochem.* 2017;41:84-97. DOI: 10.1016/j.jnutbio.2016.12.005. PMID: 28064013.
- 12 Naveen S, Siddalingaswamy M, Singit D, et al. Anti-depressive effect of polyphenols and omega-3 fatty acid from pomegranate peel and flax seed in mice exposed to chronic mild stress. *Psychiatry Clin Neurosci.* 2013;67:501-8. DOI: 10.1111/pcn.12100. PMID: 24152226.
- 13 Tabei SMB, Tamadon A, Rahmanifar F, et

- al. Xenograft of mus musculus ovary in the uterus of rattus norvegicus after induction of pseudopregnancy. *Comp Clin Pathol*. 2016;25:1065-70. DOI: 10.1007/s00580-016-2314-1.
- 14 Bettaieb A, Prieto MAV, Lanzi CR, et al. (-)-Epicatechin mitigates high-fructose-associated insulin resistance by modulating redox signaling and endoplasmic reticulum stress. *Free Radic Biol Med*. 2014;72:247-56. DOI: 10.1016/j.freeradbiomed.2014.04.011. PMID: 24746618.
 - 15 Xu J, Dun J, Yang J, et al. Letrozole Rat Model Mimics Human Polycystic Ovarian Syndrome and Changes in Insulin Signal Pathways. *Med Sci Monit*. 2020;26:e923073. DOI: 10.12659/MSM.923073. PMID: 32638705.
 - 16 Zhao H, Zhang J, Cheng X, et al. Insulin resistance in polycystic ovary syndrome across various tissues: an updated review of pathogenesis, evaluation, and treatment. *J Ovarian Res*. 2023;16:9. DOI: 10.1186/s13048-022-01091-0. PMID: 36631836.
 - 17 Kafali H, Iriadam M, Ozardalı I, et al. Letrozole-induced polycystic ovaries in the rat: a new model for cystic ovarian disease. *Arch Med Res*. 2004;35:103-8. DOI: 10.1016/j.arcmed.2003.10.005. PMID: 15010188.
 - 18 Komal F, Khan MK, Imran M, et al. Impact of different omega-3 fatty acid sources on lipid, hormonal, blood glucose, weight gain and histopathological damages profile in PCOS rat model. *J Transl Med*. 2020;18:349. DOI: 10.1186/s12967-020-02519-1. PMID: 32928224.
 - 19 Ouladsahebmadarek E, Khaki A, Khanahmadi S, et al. Hormonal and metabolic effects of polyunsaturated fatty acid (omega-3) on polycystic ovary syndrome induced rats under diet. *Iran J Basic Med Sci*. 2014;17:123-7. PMID: 24711896.
 - 20 Garedaghi Y, Bahavarnia SR. Repairing Effect of Allium Cepa on Testis Degeneration Caused by Toxoplasma Gondii in The Rat. *Int J Women's Health Reproduction Sci*. 2014;2. DOI: 10.15296/ijwhr.2014.12.
 - 21 Siavashpour A, Khalvati B, Azarpira N, et al. Poly (ADP-Ribose) polymerase-1 (PARP-1) overactivity plays a pathogenic role in bile acids-induced nephrotoxicity in cholestatic rats. *Toxicol Lett*. 2020;330:144-58. DOI: 10.1016/j.toxlet.2020.05.012. PMID: 32422328.
 - 22 Ahmadi A, Niknahad H, Li H, et al. The inhibition of NFκB signaling and inflammatory response as a strategy for blunting bile acid-induced hepatic and renal toxicity. *Toxicol Lett*. 2021;349:12-29. DOI: 10.1016/j.toxlet.2021.05.012. PMID: 34089816.
 - 23 Jamshidzadeh A, Heidari R, Mohammadi-Samani S, et al. A comparison between the nephrotoxic profile of gentamicin and gentamicin nanoparticles in mice. *J Biochem Mol Toxicol*. 2015;29:57-62. DOI: 10.1002/jbt.21667. PMID: 25293820.
 - 24 Socci D, Bjugstad K, Jones H, et al. Evidence that oxidative stress is associated with the pathophysiology of inherited hydrocephalus in the H-Tx rat model. *Exp Neurol*. 1999;155:109-17. DOI: 10.1006/exnr.1998.6969. PMID: 9918710.
 - 25 Mariutti LRB. Lipid Peroxidation (TBARS) in Biological Samples. In: Betim Cazarin CB, editor. *Basic Protocols in Foods and Nutrition*. New York, NY: Springer US; 2022.p.107-13.
 - 26 Heidari R, Taheri V, Rahimi HR, et al. Sulfasalazine-induced renal injury in rats and the protective role of thiol-reductants. *Ren Fail*. 2016;38:137-41. DOI: 10.3109/0886022X.2015.1096731. PMID: 26479898.
 - 27 Heidari R, Babaei H, Roshangar L, et al. Effects of enzyme induction and/or glutathione depletion on methimazole-induced hepatotoxicity in mice and the protective role of N-acetylcysteine. *Adv Pharm Bull*. 2014;4:21-8. DOI: 10.5681/apb.2014.004. PMID: 24409405.
 - 28 Katalinic V, Modun D, Music I, et al. Gender differences in antioxidant capacity of rat tissues determined by 2, 2'-azinobis (3-ethylbenzothiazoline 6-sulfonate; ABTS) and ferric reducing antioxidant power (FRAP) assays. *Comp Biochem Physiol C Toxicol Pharmacol*. 2005;140:47-52. DOI: 10.1016/j.cca.2005.01.005. PMID: 15792622.
 - 29 Heidari R, Niknahad H. The Role and Study of Mitochondrial Impairment and Oxidative Stress in Cholestasis. *Methods Mol Biol*. 2019;1981:117-32. DOI: 10.1007/978-1-4939-9420-5_8. PMID: 31016651.
 - 30 Alía M, Horcajo C, Bravo L, et al. Effect of grape antioxidant dietary fiber on the total antioxidant capacity and the activity of liver antioxidant enzymes in rats. *Nutr Res*. 2003;23:1251-67. DOI: 10.1016/s0271-5317(03)00131-3.
 - 31 Ullah A, Jahan S, Razak S, et al. Protective effects of GABA against metabolic and reproductive disturbances in letrozole induced polycystic ovarian syndrome in rats. *J Ovarian Res*. 2017;10:62. DOI: 10.1186/s13048-017-0359-7. PMID: 28915843.
 - 32 Skarra DV, Hernández-Carretero A, Rivera AJ, et al. Hyperandrogenemia induced by letrozole treatment of pubertal female mice results in

- hyperinsulinemia prior to weight gain and insulin resistance. *Endocrinology*. 2017;158:2988-3003. DOI: 10.1210/en.2016-1898. PMID: 28911175.
- 33 Rahmani E, Samimi M, Ebrahimi FA, et al. The effects of omega-3 fatty acids and vitamin E co-supplementation on gene expression of lipoprotein (a) and oxidized low-density lipoprotein, lipid profiles and biomarkers of oxidative stress in patients with polycystic ovary syndrome. *Mol Cell Endocrinol*. 2017;439:247-55. DOI: 10.1016/j.mce.2016.09.008. PMID: 27619403.
- 34 Karakas SE, Perroud B, Kind T, et al. Changes in plasma metabolites and glucose homeostasis during omega-3 polyunsaturated fatty acid supplementation in women with polycystic ovary syndrome. *BBA Clin*. 2016;5:179-85. DOI: 10.1016/j.bbacli.2016.04.003. PMID: 27182493.
- 35 Munro IA, Garg ML. Prior supplementation with long chain omega-3 polyunsaturated fatty acids promotes weight loss in obese adults: a double-blinded randomised controlled trial. *Food Funct*. 2013;4:650-8. DOI: 10.1039/c3fo60038f. PMID: 23396496.
- 36 Rajan RK, Balaji B. Soy isoflavones exert beneficial effects on letrozole-induced rat polycystic ovary syndrome (PCOS) model through anti-androgenic mechanism. *Pharm Biol*. 2017;55:242-51. DOI: 10.1080/13880209.2016.1258425. PMID: 27927075.
- 37 Teede HJ, Joham AE, Paul E, et al. Longitudinal weight gain in women identified with polycystic ovary syndrome: results of an observational study in young women. *Obesity (Silver Spring)*. 2013;21:1526-32. DOI: 10.1002/oby.20213. PMID: 23818329.
- 38 Shoelson SE, Lee J, Goldfine AB. Inflammation and insulin resistance. *J Clin Invest*. 2006;116:1793-801. DOI: 10.1172/JCI29069. PMID: 16823477.
- 39 Reddy PS, Begum N, Mutha S, et al. Beneficial effect of Curcumin in Letrozole induced polycystic ovary syndrome. *Asian Pacific J Reproduction*. 2016;5:116-22. DOI: 10.1016/j.apjr.2016.01.006.
- 40 Khadge S, Thiele GM, Sharp JG, et al. Long-chain omega-3 polyunsaturated fatty acids decrease mammary tumor growth, multiorgan metastasis and enhance survival. *Clin Exp Metastasis*. 2018;35:797-818. DOI: 10.1007/s10585-018-9941-7. PMID: 30327985.