

ORIGINAL ARTICLE

The Effect of Feeding Genetically Modified Soybean on Histopathology of Organs in Sprague-Dawley Rats

Elham Ashrafi-Dehkordi^{1,2*}, Amin Derakhshanfar^{3,4,5}, Abdolvahab Alborzi¹, Gholamreza Pouladfar¹, Siavash Babajafari¹, Mehdi Kian³, Gholam Hossein Darya³, Zohreh Foladi³, Seyed Mohammad Mazloomi²

1. Clinical Microbiology Research Center, Nemazee Hospital, Shiraz University of Medical Sciences, Shiraz, Iran

2. Nutrition Research Center, Department of Food Hygiene and Quality Control, School of Nutrition and Food Sciences, Shiraz University of Medical Sciences, Shiraz, Iran.

3. Department of Comparative Biomedical Sciences, School of Advanced Medical Sciences and Technologies, Shiraz University of Medical Sciences, Shiraz, Iran

4. Diagnostic Laboratory Sciences and Technology Research Center, School of Paramedical Sciences, Shiraz University of Medical Sciences, Shiraz, Iran

5. Center of Comparative and Experimental Medicine, Shiraz University of Medical Sciences, Shiraz, Iran

ARTICLE INFO

Keywords:

Food safety
Genetically modified
Soybean
Histopathology
Rat

*Corresponding author:

Elham Ashrafi-Dehkordi, PhD;
Department of Food Hygiene and
Quality Control,
School of Nutrition and Food
Sciences, Shiraz University of
Medical Sciences,
Shiraz, Iran.

Tel: +98-71-37258099

Email: elhamashrafi@gmail.com

Received: May 5, 2022

Revised: August 5, 2022

Accepted: August 10, 2022

ABSTRACT

Background: Concerns about the negative impacts of genetically modified (GM) crops have grown worldwide, necessitating research to determine robust standards. The scientific community has focused on unacceptably harmful impacts of diets consisting of GM crops. Animal experiments are providing valuable and important information regarding the safety of GM crops for both animal and human consumption. In this regard in this study, the effects of a diet containing 70% GM soybean on organs of rats were investigated.

Methods: Twenty four male Sprague-Dawley rats were randomly assigned to two groups and were fed with a diet containing either (70%) GM soybean or (0%) GM soybean (control) for 120 days. Histopathological examination and appearance of organs were compared between rats fed non-GM soybean and those fed GM soybean.

Results: All rats fed GM soybean diet and non-GM soybean diet had normal small intestine, large intestine, stomach, cecum and testes and no histopathological changes were observed. But, some histopathological alterations were seen in the brain, heart, lungs, liver, kidneys, and spleen in two groups; although, the Fisher's Exact test showed that there were no statistically significant differences ($p > 0.05$) between the two groups in terms of the frequency of normal and abnormal parts of them.

Conclusion: Regardless of whether the diet consisted of GM or non-GM feed ingredients, the alterations were seen in a similar range in both groups.

Please cite this article as: Ashrafi-Dehkordi E, Derakhshanfar A, Alborzi A, Pouladfar GR, Babajafari S, Kian M, Darya GH, Foladi Z, Mazloomi SM. The Effect of Feeding Genetically Modified Soybean on Histopathology of Organs in Sprague-Dawley Rats. Int J Nutr Sci. 2022;7(3):171-178. doi: 10.30476/IJNS.2022.96866.1203.

Introduction

The global cultivation of genetically modified

(GM) crops for food and feed reached 191.7 million hectares in 26 countries in 2018 (1). In

many countries, over 200 different GM crops with varying features have been approved for eating (2). The majority of GM crops have one or more new genes that improve them against herbicide resistance, insect or disease resistance, and salt and drought tolerance (3, 4). Ingredients such as corn syrup, fats/oils, starch, proteins, colorants, flavors, and other products derived from GM crops can be found in the livestock feed as well as in the human food (5).

Soybeans are a major commercial crop with high oil and protein content that are used for human consumption and animal feeding all over the world (6) and are under influence of various factors which might result in low quality products. For instance, there are concerns about weed threat, which results in poorer soybean yields (7). In this regard, herbicide-resistant GM crops can help increase crop yields by reducing weed pressure and reducing herbicide use, which reduces crop residues and pollution (8). Expression of the enolpyruvate shikimate-3-phosphate synthase (*EPSPS*) gene confers the soybean resistance to *Roundup* herbicides (9). Globally, GM soybeans have the highest adoption rate, accounting for 95.9 million hectares of GM agricultural land, which accounts for 78 percent of global soybean production (1).

The first transgenic organism was developed in 1970, and arguments over the commercialization of GM crops quickly followed (10). Following the publication of the first report on genetically modified organisms (GMOs) environmental concerns, the scientific community began to focus on the damages that are unacceptable, as well as the methodologies for assessing such consequences (11). A common concern in most countries is the consumption of products (e.g. milk, meat, and eggs) derived from animals fed GM feed (12). The debate on the effects of GM food and feed on the humans and animals health is still in progress. Many publications have reviewed the safety of GM crops in animals and humans. Many studies have found relatively minor differences between GM and non-GM feed groups that were not biologically significant (9, 13-15).

They concluded that the GM feed are as safe as the non-GM (9, 13-15). However, there are studies that indicate serious health problems related to the GM crops consumption, including immune problems, infertility, insulin dysregulation, accelerated aging, and changes in vital organs and the gastrointestinal tract. They stated that the risk of GM crops cannot be overlooked, and that further research is needed to uncover potential long-term impacts of GM food intake, which could aid in post-market surveillance (16, 17). The consumption of GM crops has been

recently increased, which means evaluating GM crops is more necessary. So in this study, we assessed the biological hazards associated with the GM soybean feeding in rats based on histopathological examination.

Materials and Methods

Twenty-four healthy-looking male Sprague-Dawley (SD) rats, approximately 8-weeks old and weighting an average of 263 ± 16 g were obtained from Center of Comparative and Experimental Medicine, Shiraz University of Medical Sciences, Shiraz, Iran. The animal room was maintained at a temperature of $22 \pm 2^\circ\text{C}$ with a relative humidity of $60\% \pm 5\%$ and a 12-h light/12-h dark cycles. After acclimation, rats were randomly divided into 2 experimental groups ($n=12/\text{group}$). The rats received food and water *ad libitum*. During two weeks of acclimatization, all of the rats were fed the rodent basic feed. Transgenic soybean (GM soybean) and traditional soybean (non-GM soybean) were incorporated into rodent diets at concentration of 70% (w/w). These diets were produced in accordance with AIN93M guidelines (18) and the ethical approval was granted by Ethical Committee of Shiraz University of Medical Sciences (IR.SUMS.REC.1399.1342).

At the end of the 120-day experimental period, after sacrificing by using ketamine, tissue samples of vital organs (brain, heart, liver, lungs, kidney, spleen, small intestine, large intestine, stomach, cecum, testes) were collected and fixed in 10% neutral buffered formalin (pH: 7.4, Sigma–Aldrich, Saint Louis, USA). After preparation of animal tissues from the non-GM soybean group and GM soybean group, serial sections of paraffin-embedded tissues of 5- μm thicknesses were cut by microtome and stained with hematoxylin and eosin (H&E) and studied under a light microscope.

Obtained data were analyzed using IBM SPSS Statistics for Windows (version 21, IBM Corp., NY, and USA). Fishers Exact test analysis was used to study the relationships between the abnormality of organs and diet. Differences between values were considered statistically significant at a ($p < 0.05$).

Results

Selected organs to evaluate the histological changes associated with the GM soybean feeding in rats based on examined histological parameters such as brain, heart, lungs, liver, kidney, spleen, small intestine, large intestine, stomach, testes were illustrated in Table 1. The brains of all rats in the GM soybean group and four rats in the non-GM soybean group were abnormal histologically (Table 1). Among the changes observed in the

Table 1: Summary of microscopic pathology observations.

Variable	Observation	No. of rats in	
		Non GMO	GMO
Brain	Normal	3	0
	Thrombosis of the meningeal vessel	1	0
	Massive hemorrhage in meninge and encephalomalacia	1	0
	Hemorrhage in white matter of cerebellum	1	0
	Micro gliosis, Focal micro gliosis, Nodular gliosis	2	4
	cerebral hemorrhage	0	2
	Meningeal hemorrhage	0	4
	Hemorrhage of choroid plexus (other parts of the brain are normal)	0	1
	Periventricular necrosis	0	1
lungs	Meningitis	0	1
	Normal	4	6
	Interstitial pneumonia	2	1
	Pulmonary hemorrhage	1	1
Heart	Normal	1	0
	Myocardial necrosis and fibrosis, Infarction	6	3
	leaflet myxoid degeneration, endocardial non neoplastic proliferative mass and cellular vacuolation	1	0
	Thrombosis and myocarditis	1	0
	Hemorrhage	4	5
	Myocarditis	1	0
	Dilation of sub epicardial capillaries	1	3
Spleen	Degeneration and epicarditis	1	0
	Myocardial degeneration, suppurative myocarditis ,cartilaginous metaplasia and ossification	0	1
	Normal	6	3
	Metaplastic capsule and splenic cyst with squamous metaplasia	1	2
	Lymphoid depletion in a few of white pulps	0	1
Liver	Severe Congestion	0	1
	Normal	4	0
	Congestion	1	0
	Portal lymphocytic hepatitis	1	3
Kidney	Biliary hyperplasia	3	7
	Normal	4	5
	Mild epithelial changes	1	1
	Severe Congestion	2	0
	Per glomerular interstitial lymphocytic periglomerular	0	1

GMO: Genetically modified organism

brain, hemorrhage in different parts of the brain was the most frequent in the GM group (Figure 1). However, the Fisher's Exact test showed that there was not any statistically significant difference ($p>0.05$) between the two groups in terms of the frequency of normal and abnormal different parts of the brain (Table 2).

The hearts of all rats in the GM soybean group and six rats in the non-GM soybean group were abnormal histologically (Table 1). Among the changes observed in the heart, dilation of subepicardial capillaries and necrosis in GM group and hemorrhage in both groups were the most frequent (Figure 2). However, the Fisher's Exact test showed that there was no statistically significant difference ($p>0.05$) between the two groups in terms of the frequency of normal

and abnormal parts of the heart (Table 2).

Six rats from the non-GM soybean group and three rats from the GM soybean group had normal spleen without any histological abnormalities after 120-day (Table 1). Some rats on a diet containing GM soybean showed splenic cyst with squamous metaplasia, severe congestion and lymphoid depletion in a few of white pulps (Figure 3). One rat on a diet containing non-GM soybean showed a metaplastic capsule (Figure 3). However, the Fisher's Exact test showed that there was not any statistically significant difference ($p>0.05$) between the two groups in terms of the frequency of normal and abnormal parts of the spleen (Table 2).

There were no histological alterations in the lungs of four rats from the non-GM soybean group and six

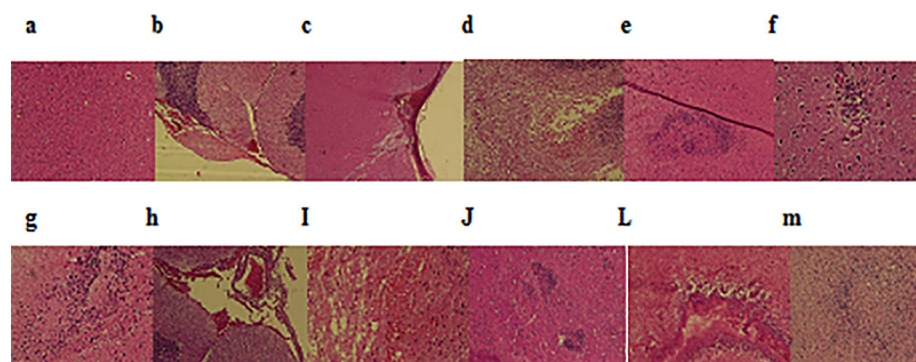


Figure 1: The tissue sections showing the histopathological results of the brain examination, HE. 100x. Upper panel, (a-f) are representatives of rats fed on diet containing non-GM soybean. a) Normal, b) Thrombosis of the meningeal vessel, c) Massive hemorrhage in meninges and encephalomalacia, d) Hemorrhage in white matter of cerebellum, e) Microgliosis, and f) Nodular gliosis. Lower panel (g-m) are representatives of rats fed on diet containing GM soybean. g) Focal microgliosis, h) Meningeal hemorrhage, i) Cerebral hemorrhage, j) Microgliosis, l) Periventricular necrosis, and m) Nodular gliosis.

Table 2: Results of the Fisher's Exact test of number of normal and abnormal rats in control and GM soybean groups.

Organ	No. of rats	GMO	Non-GMO	P value
Brain	Normal	0	3	0.1 ^{ns}
	Abnormal	7	4	
lungs	Normal	6	4	0.5 ^{ns}
	Abnormal	1	3	
Heart	Normal	0	1	1 ^{ns}
	Abnormal	7	6	
Spleen	Normal	3	6	0.2 ^{ns}
	Abnormal	4	1	
Liver	Normal	3	4	0.07 ^{ns}
	Abnormal	4	3	
Kidney	Normal	5	4	1 ^{ns}
	Abnormal	2	3	

GMO: Genetically modified organism Statistically significant at $p < 0.05$, ns: no statistically significant.




Figure 2: The tissue sections showing the histopathological results of the heart examination, HE. 100x. Upper panel, (a-f) are representatives of rats fed on diet containing non-GM soybean. a) Normal, b) Myocardial necrosis and fibrosis, c) Leaflet myxoid degeneration, d) Infarction and fibrosis, e) Thrombosis and myocarditis, f) Hemorrhage of tunica adventitia of aorta and epicardium and also in atrial wall, and g) Epicarditis. Lower panel (h-n) are representatives of rats fed on diet containing GM soybean. h) Suppurative myocarditis, i) Myocardial degeneration, j) Subendocardial hemorrhage, l) Hemorrhage of tunica adventitia of aorta, m) Necrosis and hemorrhage, and n) Necrosis and fibrosis.

rats from the GM soybean group (Table 1). However, two rats on a diet containing non-GM soybean and one rat on a diet containing GM soybean showed interstitial pneumonia and one rat from each group showed pulmonary hemorrhage (Figure 4A). The Fisher's Exact test showed that there was no

statistically significant difference ($p > 0.05$) between the two groups in terms of the frequency of normal and abnormal parts of the lungs (Table 2). In case of the lungs, observed changes were similar in regard to their appearance in both groups, regardless of the tested GM feed components.

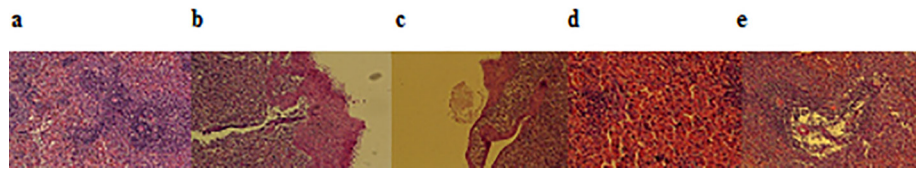


Figure 3: The tissue sections showing the histopathological results of the spleen examination, HE, 100x. (a-b) are representatives of rats fed on diet containing non-GM soybean. a) Normal, and b) Metaplastic capsule. (c-e) are representatives of rats fed on diet containing GM soybean. c) Splenic cyst with squamous metaplasia, d) severe congestion, and e) lymphoid depletion in a few of white pulps.

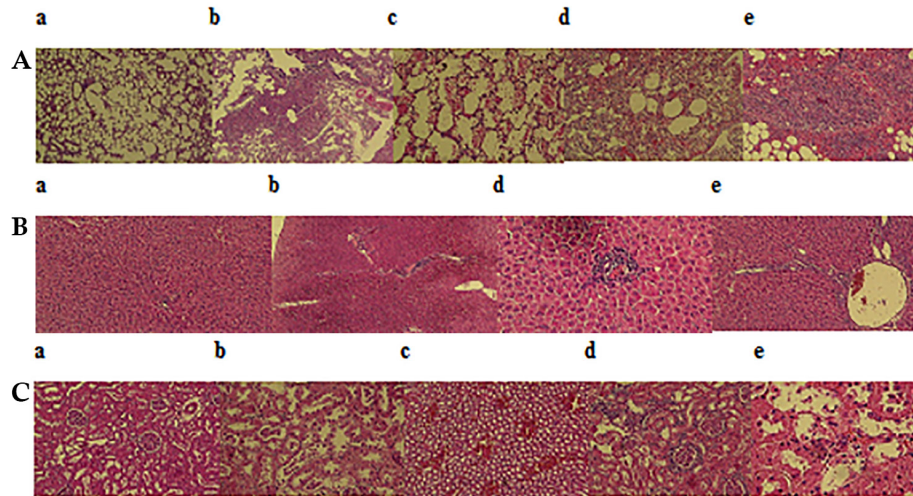


Figure 4: A: The tissue sections showing the histopathological results of the lung examination, HE, 100x. (a-c) are representatives of rats fed on diet containing non-GM soybean. a) Normal, b) Interstitial pneumonia, and c) Pulmonary hemorrhage. (d-e) are representatives of rats fed on diet containing GM soybean. d) Pulmonary hemorrhage, and e) interstitial pneumonia. B: The tissue sections showing the histopathological results of the liver examination, HE, 100x. (a-b) are representatives of rats fed on diet containing non-GM soybean. a) Normal, and b) Congestion, portal lymphocytic hepatitis and biliary hyperplasia. (b-e) are representatives of rats fed on diet containing GM soybean, d) Portal lymphocytic hepatitis, and e) biliary hyperplasia. C: The tissue sections showing the histopathological results of the kidney examination, HE, 100x. (a-c) are representatives of rats fed on diet containing non-GM soybean. a) Normal, b) Mild epithelial changes, and c) Severe congestion. (d-e) are representatives of rats fed on diet containing GM soybean, d) Periglomerular interstitial lymphocytic nephritis, and e) Mild epithelial changes (necrosis).

Because of its central function in regulating the entire metabolism, the liver is a good model for observing the effects of a diet. Four rats from non-GM soybean group showed a normal liver structure without any histopathological changes and three rats of this group showed histopathological alterations as congestion, portal lymphocytic hepatitis and biliary hyperplasia (Figure 4B). But, all rats in GM soybean group showed histopathological modifications as portal hepatitis lymphocytic and biliary hyperplasia (Table 1). However, the Fisher's Exact test showed that there was not a statistically significant difference ($p>0.05$) between the two groups in terms of the frequency of normal and abnormal parts of the liver (Table 2).

Four rats from non-GM soybean group and five rats from GM soybean group had normal kidney without any histopathological changes. However, two rats on a diet containing GM soybean showed Periglomerular interstitial lymphocytic nephritis and mild epithelial alterations (Figure 4C). Three rats on a diet containing non-GM soybean showed

mild epithelial changes and severe congestion. The Fisher's Exact test showed that there was not a statistically significant difference ($p>0.05$) between the two groups in terms of the frequency of normal and abnormal different parts of the kidney (Table 1). All rats on a diet containing GM soybean and on a diet containing non-GM soybean, demonstrated normal small intestine, large intestine, cecum and stomach without any histopathological changes. All rats on a diet containing GM soybean and on a diet containing non-GM soybean, illustrated normal testes without any histopathological changes.

Discussion

In the histological parameters of present study, all rats of control and experimental groups demonstrated normal small intestine, large intestine, cecum, stomach and testes. The Fisher's Exact tests showed that there were not a statistically significant difference ($p>0.05$) between the two groups in terms of the frequency of normal and abnormal parts of brain, heart, liver, spleen, lungs and kidney.

The use of GM crops in animal feed is increasing continually, which has sparked a considerable controversy regarding GM feeds. Despite a number of researches which demonstrated GM crops did not have any effects on animal health, the safety of this feed is still debated in many countries (19-21). Kulikov has shown opposite opinions to exist that were experimentally documented (22). Therefore, for the public to accept these products, safety assessments of new GM products should be performed. Animal experiments provide important information regarding the safety of GM plants for both human and animal consumption (23).

In this study, various histopathological changes were seen in brain, heart, liver, spleen, lungs and kidney of both groups. For example, the liver of all rats in the GM soybean group and three rats in control group were abnormal histologically. According to some studies, these histopathological changes may have different reasons (e.g., age and strain of animal). Delaney *et al.* (21) reported a few of rats had focal lymphocytic foci in their livers and they stated that GM soybean feeding may impact on liver during aging in Sprague–Dawley rats.

Eissa *et al.* (2) mentioned that histopathological changes in liver (basophilic focal necrotic areas, spontaneously focal and multifocal angiectasis) of GM soybean group may occur with age. Appenzeller *et al.* (24) observed some changes in liver and inflammatory cell infiltrates in lungs in a number of rats but they mentioned that they are common findings among experimental rats of this strain and age. Qi *et al.* (25) reported some changes in a number of rats tested with transgenic soybeans, but they pointed out that these changes are common in this strain. Tang *et al.* also reported that the histopathological changes in rat were fed GM rice for 90 days occur spontaneously in Sprague–Dawley rats of this age (26).

Based on our finding, no group-related histopathological observations were presented in kidney. Smith (27) demonstrated that feeding rats with MON 863 Bt maize led to nephritis and lesions in kidney and liver. So, Kilic and Akay (28) observed some changes in kidney (e.g. minimal tubular degenerations and enlargements in parietal layer of Bowman's capsule at different ratios in groups). Reduction in average short and long diameter of glomeruli and glomerular volume in rats on a standard diet (containing 20% non-transgenic maize) and rats on a diet (containing 20% transgenic Bt maize) were statistically different from controls while changes in the cortical thickness were not significant between groups (28). Song *et al.* observed pulmonary interstitial hemorrhage in the control and treatment

groups, but they stated that this is a common finding among experimental rats of this strain and age (29).

The histopathological changes of heart and brain were particularly surprising in control and treatment groups. Some studies have suggested that histopathological changes in the heart may be due to aging and were not considered to the test diets containing the GMO (26, 29). Although, no previous studies have looked at the brain, the mechanisms responsible for these severe changes in the brain are still unknown. In this study, a typical histopathological observation of testes, intestine and stomach were not visible. Similar to our results, Tang *et al.* reported the histopathological trial revealing no changes in the intestinal tract of rats that were fed by genetically modified rice (26).

However, several studies have found the opposite of our findings, for example, transgenic soybean generated moderate inflammation in salmon's distal colon (30). Moreover, Fares and El-Sayed observed that feeding transgenic potato to mice resulted in proliferative cell growth as well as abnormal and damaged cells in the small intestine (31). According to Vecchio *et al.*, mice fed GM soybean for more than 8 months had nuclear transcription anomalies in their testes (32). In addition, they found that the nuclear pore density was lower and the number of perichromatin granules was higher for the GM-fed mice of all ages (32). Moreover, the smooth endoplasmic reticulum of Sertoli cells was larger for the GM-fed mice (32). Keshani *et al.* (33) reported that GM foods had no adverse effects on fertility indices and on infertility indices (sperm head, sperm motility, sperm abnormality) (34).

Conclusion

Regardless of the diets content of GM soybean or free from GM soybean, histopathological changes were observed in some organs. The changes in the kidneys, heart and some alterations of liver might be due to age. The small intestine, large intestine, cecum, stomach and testes did not show any histopathological modifications. No previous studies have looked at the brain, so more research with different doses, longer durations, and larger sample size is required. However, safety testing, effective policies and food labeling should all be developed.

Acknowledgement

The authors are grateful to members of the Professor Alborzi Clinical Microbiology Research Center, the Center of Comparative and Experimental Medicine and School of Nutrition and Food Sciences of Shiraz University of Medical

Sciences, Shiraz, Iran. This work was supported by the Shiraz University of Medical Sciences (Project no: IR.SUMS.REC.1399.1342).

Conflict of Interest

None declared.

References

- ISAAA. Global Status of Commercialized Biotech/GM Crops. ISAAA Brief No. 54. ISAAA: Ithaca, NY; 2018..
- Eissa MI, El-Sherbiny MA, Ibrahim AM, et al. Biochemical and Histopathological studies on female and male Wistar rats fed on genetically modified soybean meals (Roundup Ready). *J Basic Appl Zool.* 2019;80:1-2. DOI:10.1186/s41936-019-0114-2.
- Ashrafi-Dehkordi E, Alemzadeh A, Tanaka N, et al. Effects of vacuum infiltration, Agrobacterium cell density and acetosyringone concentration on Agrobacterium-mediated transformation of bread wheat. *J Consum Protect Food Safe.* 2021;16:59-6. 9. DOI: 10.1007/s00003-020-01312-y.
- Ashrafi-Dehkordi E, Alemzadeh A, Tanaka N. Agrobacterium-mediated transformation of ovary of bread wheat (*Triticum aestivum* L.) with a gene encoding a tomato ERF protein. *Plant Cell Biotechnol Mol Boil.* 2018;24-33.
- Uzogara SG. The impact of genetic modification of human foods in the 21st century: A review. *Biotechnol Adv.* 2000;18:179-206. DOI:10.1016/s0734-9750(00)00033-1. PMID: 14538107.
- Hartman GL, West ED, Herman TK. Crops that feed the World 2. Soybean—worldwide production, use, and constraints caused by pathogens and pests. *Food Sec.* 2011;3:5-17. DOI:10.1007/s12571-010-0108-x.
- Datta A, Ullah H, Tursun N, et al. Managing weeds using crop competition in soybean [*Glycine max* (L.) Merr.]. *Crop Protec.* 2017;95:60-8. DOI:10.1016/j.cropro.2016.09.005.
- Dill GM, CaJacob CA, Padgett SR. Glyphosate-resistant crops: adoption, use and future considerations. *Pest Manag Sci.* 2008;64:326-31. DOI: 10.1002/ps.1501. PMID: 18078304
- Ashrafi-Dehkordi E, Mazloomi SM, Hemmati F. A comparison of DNA extraction methods and PCR-based detection of GMO in textured soy protein. *J Consum Protect Food Safe.* 2021;16:51-7. DOI: 10.1007/s00003-020-01300-2.
- NIH. NIH Guidelines for Research Involving recombinant or Synthetic Nucleic Acid Molecules, 2013. National Institute of Health, Office of Science Policy. US Department of Health and Human Services. http://osp.od.nih.gov/sites/default/files/NIH_Guidelines_0.
- Sharples FE. Spread of organisms with novel genotypes: thoughts from an ecological perspective. *Recomb DNA Tech Bull.* 1983;6:43-56. PMID:6576449.
- Wong AY, Chan AW. Genetically modified foods in China and the United States: A primer of regulation and intellectual property protection. *Food Sci Hum Well.* 2016;5:124-40. DOI: 10.1016/j.fshw.2016.03.002
- Trabalza-Marinucci M, Brandi G, Rondini C, et al. A three-year longitudinal study on the effects of a diet containing genetically modified Bt176 maize on the health status and performance of sheep. *Livestock Sci.* 2008;113:178-90. DOI: 10.1016/j.livsci.2007.03.009.
- Domingo JL. Safety assessment of GM plants: An updated review of the scientific literature. *Food Chem Toxicol.* 2016;95:12-8. DOI:10.1016/j.fct.2016.06.013. PMID: 27317828.
- Zoller O, Rhyn P, Rupp H, et al. Glyphosate residues in Swiss market foods: monitoring and risk evaluation. *Food Addit Contam Part B Surveill.* 2018;11:83-91. DOI: 10.1080/19393210.2017.1419509. PMID:29284371.
- El-Shamei ZS, Gab-Alla AA, Shatta AA, et al. Histopathological changes in some organs of male rats fed on genetically modified corn (Ajeeb YG). *J Am Sci.* 2012;8:684-96.
- Vecchio L, Cisterna B, Malatesta M, et al. Ultrastructural analysis of testes from mice fed on genetically modified soybean. *Europ J Histochem.* 2004;449-54. PMID: 15718213.
- Reeves PG, Nielsen FH, Fahey Jr GC. AIN-93 purified diets for laboratory rodents: final report of the American Institute of Nutrition ad hoc writing committee on the reformulation of the AIN-76A rodent diet. *J Nutr.* DOI: 10.1093/jn/123.11.1939. PMID: 8229312.
- Chukwudebe A, Privalle L, Reed A, et al. Health and nutritional status of Wistar rats following subchronic exposure to CV127 soybeans. *Food Chem Toxicol.* 2012;50:956-71. DOI: 10.1016/j.fct.2011.11.034. PMID: 22146086.
- McNaughton J, Roberts M, Smith B, et al. Comparison of broiler performance when fed diets containing event DP-356043-5 (Optimum GAT), nontransgenic near-isoline control, or commercial reference soybean meal, hulls, and oil. *Poult sci.* 2007;86:2569-81. DOI: 10.3382/ps.2007-00140. PMID: 18029803.
- Delaney B, Appenzeller LM, Munley SM, et al. Subchronic feeding study of high oleic acid soybeans (event DP-305423-1) in Sprague-

- Dawley rats. *Food Chem Toxicol.* 2008; 46:3808-17. DOI: 10.1016/j.fct.2008.10.003. PMID: 18952136.
- 22 Kulikov AM. Genetically modified organisms and risks of their introduction. *Russ J Plant Physiol.* 2005;52:99-111. DOI: 10.1007/s11183-005-0015-8
- 23 Nowicki PL, Aramyan LH, Baltussen WH, et al. Study on the implications of asynchronous GMO approvals for EU imports of animal feed products. https://ec.europa.eu/agriculture/external-studies/asynchronous-gmo-approvals_en.
- 24 Appenzeller LM, Munley SM, Hoban D, et al. Subchronic feeding study of herbicide-tolerant soybean DP-356043-5 in Sprague-Dawley rats. *Food Chem Toxicol.* 2008;46:2201-13. DOI: 10.1016/j.fct.2008.02.017. PMID: 18403083.
- 25 Qi H, Xiang Z, Han G, et al. Effects of different dietary protein sources on cecal microflora in rats. *Afr J Biotechnol.* 2011;10:3704-8. DOI: 10.5897/AJB10.2677.
- 26 Tang M, Xie T, Cheng W, et al. A 90-day safety study of genetically modified rice expressing rhIGF-1 protein in C57BL/6J rats. *Transgenic res.* 2012;21:499-510. DOI: 10.1007/s11248-011-9550-6. PMID: 21910016.
- 27 Smith JM. Most Offspring died when mother rats ate genetically engineered soy. Spilling the Beans newsletter. 2005:1-4.
- 28 Kılıç A, Akay MT. A three generation study with genetically modified Bt corn in rats: Biochemical and histopathological investigation. *Food Chem Toxicol.* 2008;46:1164-70. DOI: 10.1016/j.fct.2007.11.016. PMID: 18191319.
- 29 Song H, He X, Zou S, et al. A 90-day subchronic feeding study of genetically modified rice expressing Cry1Ab protein in Sprague-Dawley rats. *Transgenic Res.* 2015;24:295-308. DOI: 10.1007/s11248-014-9844-6. PMID: 25367203.
- 30 Bakke-McKellep AM, Koppang EO, Gunnes G, et al. Histological, digestive, metabolic, hormonal and some immune factor responses in Atlantic salmon, *Salmo salar* L., fed genetically modified soybeans. *J Fish Dis.* 2007;30:65-79. DOI: 10.1111/j.1365-2761.2007.00782.x. PMID: 17298562.
- 31 Fares NH, El-Sayed AK. Fine structural changes in the ileum of mice fed on δ -endotoxin-treated potatoes and transgenic potatoes. *Nat Toxins.* 1998;6:219-33. DOI: 10.1002/(SICI)1522-7189(199811/12)6:6<219::AID-NT30>3.0.CO;2-K. PMID: 10441029.
- 32 Vecchio L, Cisterna B, Malatesta M, et al. Ultrastructural analysis of testes from mice fed on genetically modified soybean. *Europ J Hisochem.* 2004;449-54. DOI: 10.4081/920. PMID: 15718213.
- 33 Keshani P, Sharifi MH, Heydari MR et al. The effect of genetically modified food on infertility indices: a systematic review study. *Sci World J.* 2020,13;2020. DOI: 10.1155/2020/1424789. PMID: 32855628.