

ORIGINAL ARTICLE

# The Effect of *Citrullus Colocynthis* on Serum Lipid Profile and Hepatic Histology in CCl<sub>4</sub>-Induced Liver Injury Rat Model

Mina Fouzi<sup>1</sup>, Nematollah Razmi<sup>1,2\*</sup>, Davood Mehrabani<sup>3,4,5,6</sup>

1. Department of Biochemistry, Fars Science and Research Branch, Islamic Azad University, Fars, Iran
2. Department of Biochemistry, School of Veterinary Medicine, Shiraz University, Shiraz, Iran
3. Stem Cell Technology Research Center, Shiraz University of Medical Sciences, Shiraz, Iran
4. Burn and Wound Healing Research Center, Shiraz University of Medical Sciences, Shiraz, Iran
5. Comparative and Experimental Medicine Center, Shiraz University of Medical Sciences, Shiraz, Iran
6. Li Ka Shing Center for Health Research and Innovation, University of Alberta, Edmonton, AB, Canada

ARTICLE INFO

Keywords:

*Citrullus colocynthis*

Lipid profile

Fatty liver

CCl<sub>4</sub>

Rat

ABSTRACT

**Background:** Chemical drugs in treatment of liver diseases are still scare and with many complications. *Citrullus colocynthis* known as bitter apple is on of herbals that can affect liver function. This study evaluated the effect of *C. colocynthis* on serum lipid profile and hepatic tissue histology in CCl<sub>4</sub>-induced liver injury rat model.

**Methods:** In this experimental animal study, forty-two Wistar rats were randomly divided into 6 equal groups of control received 1 mL/kg of distilled water, twice a week for 2 weeks intraperitoneally (IP); sham injected with 50% CCl<sub>4</sub> identically; and experimental groups administered with just 20 mg/kg of *C. colocynthis* similarly; receipt of 20 mg/kg of *C. colocynthis* after induction of fatty liver disease by CCl<sub>4</sub>, identically; received 50 mg/kg of *C. colocynthis* in the same manner; and receipt of 50 mg/kg of *C. colocynthis* after induction of fatty liver disease by CCl<sub>4</sub>, identically. The triglyceride (TG) and cholesterol levels were determined and liver tissue changes were assessed histologically before and after interventions.

**Results:** *C. colocynthis* could decrease TG, total cholesterol (TC), high-density lipoprotein (HDL), but not low-density lipoprotein (LDL) after liver injury. *C. colocynthis* could significantly ameliorate the injured liver.

**Conclusion:** Based on the decrease in TG, TC and HDL levels and histological healing picture in hepatic tissue after administration of *C. colocynthis*, it can be recommended as an alternative medical therapy for liver injuries because it is inexpensive and is easily available. These findings can be added to the literature when targeting treatment of liver injuries.

\*Corresponding author:

Nematollah Razmi,  
Department of Biochemistry,  
Fars Science and Research,  
Shiraz Branch, Islamic Azad  
University,  
Fars, Shiraz, Iran.

Tel: +98-71-2305410

Email: [razmi@shirazu.ac.ir](mailto:razmi@shirazu.ac.ir)

Received: March 25, 2020

Revised: September 7, 2020

Accepted: September 16 2020

Please cite this article as: Fouzi M, Razmi N, Mehrabani D. The Effect of *Citrullus Colocynthis* on Serum Lipid Profile and Hepatic Histology in CCl<sub>4</sub>-Induced Liver Injury Rat Model. Int J Nutr Sci. 2020;5(4):208-213. doi: 10.30476/IJNS.2020.88244.1094.

## Introduction

The liver is one of the major organs responsible for detoxification of drugs, biotransformation of xenobiotics, and disposal of metabolism wastes.

Its role in fat absorption and the defense against microorganisms and toxins should not be ignored too (1). The metabolites from viruses, bacteria and fungi, the environmental pollutants and

chemotherapy agents can have adverse influences on the liver. Among the chemicals, carbon tetrachloride (CCl<sub>4</sub>) can lead to liver damages via NADPH-cytochrome P<sub>450</sub> as the enzymatic system that can reactivate trichloromethyl and peroxy trichloromethyl radicals (2).

These free radicals target the alkaline functional groups, unsaturated fatty acids, proteins, and other cellular macromolecules and result into lipid peroxidation in cell membrane and change the enzymatic activities and finally induce cellular damages and necrosis (3). Administration of CCl<sub>4</sub> in mice during a short period was compared with other toxins and revealed liver damages and cirrhosis identical to cirrhosis in humans after use of CCl<sub>4</sub> (4).

Fatty liver disease can be experimentally induced by administration of CCl<sub>4</sub> that was identified before (5). Non-alcoholic fatty liver disease (NAFLD) is also among liver injuries occurring when more than 5-10% of liver weight is consisted of fat and is associated with hypertension, lipid disorders, overweight, and diabetes, which are parts of metabolic syndrome (6).

Fatty liver disease can be a symptom of resistance against insulin, and that is why early detection and appropriate treatment can prevent further liver damages, that are the most important cause of mortality in patients with fatty liver disease (7). The prevalence of fatty liver disease in adults in Western countries was reported 34-46% that 70-80% of the cases are among obese population (8, 9). In Iran, the prevalence of this disease was estimated by 21.5-31.5% (10).

The effect of various herbals on liver injuries has been studied revealing inhibition of the progression of injuries after their use (11, 12). As medicinal plants are easily available and with low side effects and have reasonable prices, they are considered worthy alternative drugs in treatment of liver diseases too. Among them, *Citrullus colocynthis*, also known as Bitter Apple, is one of the tropical herbals found in several Middle East countries including Iran. It contains koulosintilin, citrulline, resinous substances, pectin materials and various minerals (13).

The seed of this plant is similar to the fruit with a bitter taste. It is composed of linoleic acid (67-73%), oleic acid (10-16%), stearic acid (5-8%), palmitic acid (9-12%) and also proteins (14). In traditional medicine, this plant is used in treatment of diabetes, jaundice, constipation, edema, fever, bacterial infections, cancer and also abortion (15). Administration of *C. colocynthis* fruit was shown to be effective in protecting the pancreatic cells from tissue damages (16). So this study was undertaken to determine the effect of *C. colocynthis* on serum lipid

profile and hepatic tissue histology in CCl<sub>4</sub>-induced liver injury rat model.

## Materials and Methods

*C. colocynthis* was purchased from herbal drug store in Shiraz, southern Iran in dried form. The plant was identified and confirmed by Department of botany, Islamic Azad University, Shiraz Branch, Shiraz, Iran. In this experimental study, the seed and pulp of *C. colocynthis* were converted into powder using a mortar. LD<sub>50</sub> of *C. colocynthis* in aqueous form was assessed and reported as 100 mg/kg as described before (17). Two different doses of 20 mg/kg and 50 mg/kg of *C. colocynthis* in aqueous form were used in this study via gavage. LD<sub>50</sub> of carbon tetrachloride (CCl<sub>4</sub>) for induction of CCl<sub>4</sub>-induced liver injury was determined to be 1.9 mL/kg based on a previous report (18). During interventions in all groups, a volume of 1 mL/kg (ratio 1:1 diluted with olive oil), twice a week for 2 weeks was administered.

In grouping of rats forty two male Wistar rats (weighing 170-250 g) were enrolled. The animals were purchased from Animal House of Shiraz University of Medical Sciences, Shiraz, Iran. Animals were kept in standard conditions of 12 hours light and 12 hours darkness, temperature of 22-20°C and a relative humidity of 40-60%. They had free access to water and food and were allowed to accommodate to their condition before the experiments. The study was approved in Ethics Committee of Shiraz Islamic Azad University (7-E-IR-MIAU.REC.80-B-1395), and all experiments were carried out based on guidelines of Iran Veterinary Organization.

The rats were randomly divided into 6 equal groups including the control group receiving just 1 mL/kg of distilled water, twice a week for 2 weeks intraperitoneally (IP), the sham group that was injected with 50% CCl<sub>4</sub> (IP, 1 mL/kg, twice a week for 2 weeks), and the experimental groups including the group that received just 20 mg/kg of *C. colocynthis* aqueous extract (IP, 1 mL/kg, twice a week for 2 weeks), the group that was administered 20 mg/kg of *C. colocynthis* after induction of liver injury by CCl<sub>4</sub> (IP, 1 mL/kg, twice a week for 2 weeks), the group received just 50 mg/kg of *C. colocynthis* (IP, 1 mL/kg, twice a week for 2 weeks), and the last group receiving 50 mg/kg of *C. colocynthis* after induction of liver injury by CCl<sub>4</sub> (IP, 1 mL/kg, twice a week for 2 weeks). Liver injury was confirmed histologically.

Following 2 weeks of CCl<sub>4</sub>-induced liver injury, a blood sample was provided from the heart of each rat under general anesthesia using ether. Blood samples were transferred into a chelate tube, and later placed in a centrifuge at 2000 rpm for 15

minutes. The serum was isolated and transferred in ependorf tubes and evaluated triglyceride (TG) and cholesterol using Pars Azmoon Company's kits. The high-density lipoprotein (HDL) and low-density lipoprotein (LDL) were assessed using Pars Azmoon Company's kits and auto analyzer machine.

Tissue sampling was carried out after CCl<sub>4</sub>-induced liver injury, as well as 2 weeks after interventions. Liver processing was conducted based on a previous study (19). In brief, 5% neutral formalin solution was used to fix the liver tissue. It was later embedded in paraffin, sliced as 5 µ thickness, and stained with H&E and visualized under microscope.

The mean±standard deviation of data was calculated using Excel software. The difference between continuous parameters was calculated using t-test. For all comparisons, P<0.05 was considered statistically significant.

## Results

A statistically significant reduction in TG level was noted when *C. colocynthis* at a dose of 50 mg/kg was administered following liver injuries caused by CCl<sub>4</sub> (P<0.05, Table 1). Regarding the total cholesterol level, the decrease was visible when 50 mg/kg of *C. colocynthis* was injected IP after induction of fatty liver disease by CCl<sub>4</sub> and the difference was statistically significant with other groups (P<0.05, Table 1). When HDL level was compared between different groups, it was shown that 50 mg/kg of *C. colocynthis* could significantly reduce the serum HDL level in rats with fatty liver disease experimentally induced by CCl<sub>4</sub> (P<0.05, Table 1).

LDL serum level did not reveal any significant change after IP injection of 20 and 50 mg/kg of *C. colocynthis* following liver injuries induced by IP injection of CCl<sub>4</sub> in experimental rats (P>0.05, Table 1). Following IP injection of 20 and 50 mg/kg of *C. colocynthis* after induction of liver injuries by CCl<sub>4</sub> in experimental rats, total cholesterol (TC)/HDL

ratio demonstrated a significant decrease (P<0.05, Table 1). Comparison of LDL/HDL ratio denoted to a significant decline after administration of 50 mg/kg of *C. colocynthis* following liver injuries induced by IP injection of CCl<sub>4</sub> in experimental rats (P<0.05, Table 1).

Figure 1 illustrates the histological findings of CCl<sub>4</sub>-induced liver injury and repair in hepatic tissue after administration of *C. colocynthis*. Infiltration of inflammatory cells happened after IP injection of CCl<sub>4</sub>. A decline in inflammatory cells and healing effect and rearrangement to normal hepatocytes were noted 2 weeks after the injection of *C. colocynthis*. A significant amelioration in hepatic tissue was illustrated by H&E staining when 50 mg/kg of *C. colocynthis* was administered.

## Discussion

The liver is armed with the endogenous system of antioxidants enzymes to counter the offending oxidative stress (20). However, when the oxidative stress is more than the neutralizing capacity, the liver would be the most vulnerable region for free radicals related tissue damage (20). The peroxide produced in the lipid metabolic process can attack hepatic cells leading to liver injury (21). The produced harmful reactive intermediates including redox-active reactants, and free radicals can cause metabolic pressure (22) that can damage hepatic cells and induce steatosis and cirrhosis (23). Collagen synthesis in hepatic stellate cells are responsible for the direct causative role of fibrogenesis in liver that is triggered by lipid peroxidation due to oxidative stress and liver damage (24).

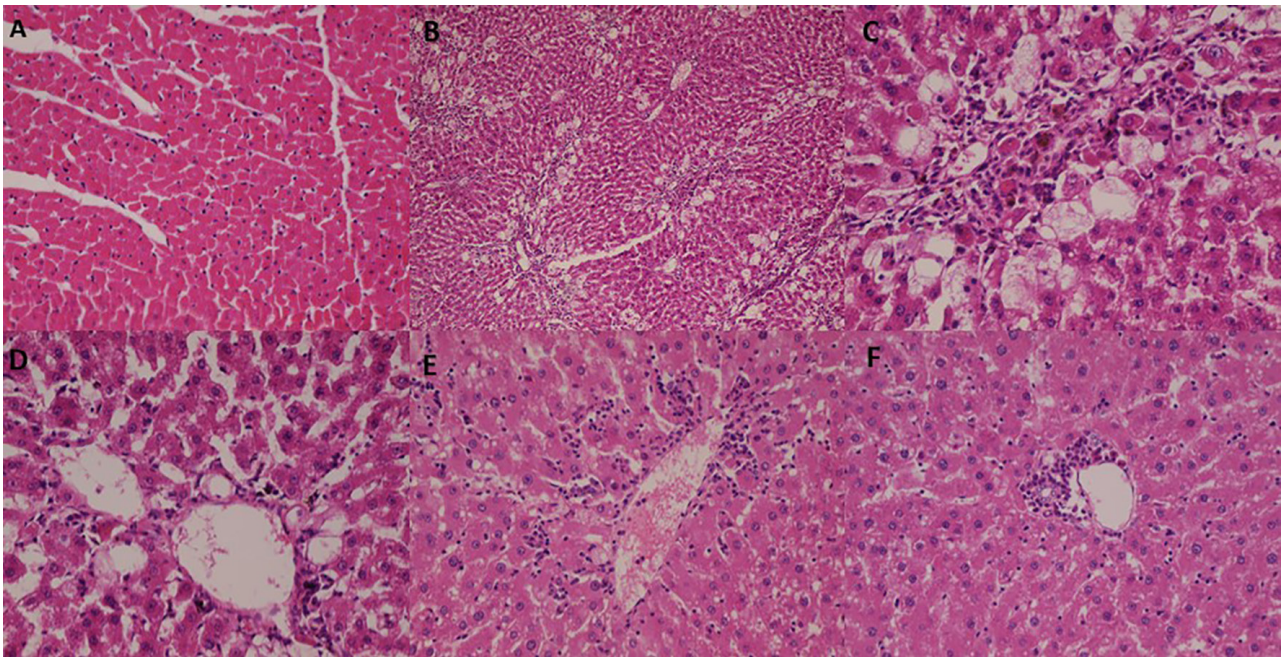
A model of CCl<sub>4</sub>-induced liver injury has been applied to assess a chemical hepatic injury. The mechanism involves liver metabolism, wherein cytochrome P450 (CYP) enzymes in the form of CCl<sub>4</sub>, the trichloromethyl radical (CCl<sub>3</sub>) (25) can impair the vital cellular processes and cause extensive cell damage and apoptosis. In apoptosis and fibrosis

**Table 1:** Comparison of lipid profile in different groups (mean±standard deviation).

Group	TC/HDL* (mg/dL)	LDL/HDL* (mg/dL)	LDL (mg/dL)	HDL* (mg/dL)	TC* (mg/dL)	TG* (mg/dL)	P value*
1	2.80±0.51	0.92±0.41	20.26±8.27	22.43±3.00	62.00±9.52	96.14±6.70	<0.05
2	3.35±0.37	1.38±0.29	38.67±6.78	28.59±2.87	95.00±6.73	138.58±2.59	<0.05
3	2.85±0.30	0.97±0.27	19.79±5.37	20.43±1.61	58.14±6.31	89.67±2.69	<0.05
4	3.82±0.55	2.22±0.58	33.87±11.35	21.88±2.04	82.86±11.22	135.27±2.43	<0.05
5	0.50±2.53	0.57±0.38	9.29±5.91	16.59±2.57	41.00±5.42	75.68±4.37	<0.05
6	4.31±0.73	2.22±0.58	38.00±5.18	17.67±2.69	74.69±3.63	95.00±5.08	<0.05

HDL: High-density lipoprotein; LDL: Low-density lipoprotein; TC: Total cholesterol; TG: Triglyceride. Group 1: control group receiving just 1 mL/kg of distilled water; Group 2. sham group receiving that was injected with 50% CCl<sub>4</sub>; Group 3: received just 20 mg/kg of *C. colocynthis* aqueous extract; Group 4: administration of 20 mg/kg of *C. colocynthis* after induction of liver injury; Group 5: received just 50 mg/kg of *C. colocynthis*; Group 6: Receiving 50 mg/kg of *C. colocynthis* after induction of liver injury (IP, 1 mL/kg, twice a week for 2 weeks). \*P value was less than 0.05.





**Figure 1:** Histological findings after injection of *C. colocynthis*. **A:** control received 1 mL/kg of distilled water ( $\times 40$ , H&E), **B:** sham received 50%  $\text{CCl}_4$  ( $\times 20$ , H&E), **C:** the group received 20 mg/kg of *C. colocynthis* ( $\times 100$ , H&E), **D:** the group received 20 mg/kg of *C. colocynthis* after induction of fatty liver disease by  $\text{CCl}_4$  ( $\times 100$ , H&E), **E:** the group received 50 mg/kg of *C. colocynthis* ( $\times 100$ , H&E), **F:** the group received 50 mg/kg of *C. colocynthis* after induction of fatty liver disease by  $\text{CCl}_4$  ( $\times 100$ , H&E).

officer, the synthesis of cellular phospholipids refers to the incorporation of phospholipids into lipoproteins and induce triglycerides accumulation (26).

The researchers have developed effective and potent natural products for the treatment of liver dysfunction with promising protection in various  $\text{CCL}_4$ -induced liver injury models (27, 28). In the studies undertaken on  $\text{CCL}_4$ -induced liver injury models, one dose of  $\text{CCl}_4$  could cause liver injuries such as necrosis, cirrhosis and cancer (29), while the easiest and fastest route of administration was reported to be by IP injection (30). Herbals have been used to lower lipid profile. Gemfibrozil was shown to lower the lipid profile in fatty liver disease (31). Statin was also demonstrated to decrease the lipid profile, specially the cholesterol level (32).

In our study we assessed the effect of *C. colocynthis* on lipid profile with significant impact on lowering TG, TC, and HDL levels in  $\text{CCl}_4$ -induced liver injury rat model at doses of 20 and 50 mg/kg, while the dose of 50 mg/kg could significantly decrease lipid profile. Daradka et al. showed hypolipidemic effects of *C. colocynthis* L. in rabbits with a decrease in cholesterol, phospholipids, and triglyceride levels (33). *C. colocynthis* at doses of 50 and 100 mg/kg was shown to have anti-diabetes effects, and without any side effects (34). Dehghani et al. in two different studies found that all doses of *C. colocynthis* were not safe and could be toxic at doses of 200 mg/kg and cause abortion in pregnant ewes (17, 35). In traditional Chinese medicine, *Ginkgo biloba* leaves

have been used to have hepatoprotective effect against  $\text{CCl}_4$ -induced hepatotoxicity in rats based on their property for inhibition of lipid peroxidative processes, and preventing GSH depletion and exertion of antioxidant activities (36).

In our study, the healing effect of *C. colocynthis* was illustrated histologically in  $\text{CCl}_4$ -induced liver injury rat model at doses of 20 and 50 mg/kg, while the effect was statistically significant at the dose of 50 mg/kg. The infiltration of inflammatory cells disappeared after administration of 50 mg/kg of *C. colocynthis* and liver arrangement returned to normal structure after injection of 50 mg/kg of *C. colocynthis*.

### Conclusion

The aqueous extract of *C. colocynthis* at a dose of 50 mg/kg was shown to decrease the levels of serum triglyceride, total cholesterol, and HDL. It could significantly ameliorate hepatic injuries and lead to healing and repairing effects in hepatic injured tissue. These findings can be added to the literature when *C. colocynthis* is targeted in fatty liver disease and hepatic injuries.

### Acknowledgement

This study was financially supported by Islamic Azad University, Shiraz Branch (7-E-IR-MIAU.REC.80-B-1395).

### Conflict of Interest

None declared.

## References

- 1 Rabbani-Haghighi N, Naghsh N, Mehrabani D. The comparison of pretreatment effects of boiled coffee and curcuma longa on serum albumin as a liver indicator in male rats injected with thioacetamide. *J Fasa Univ Sci.* 2014;4:58-66.
- 2 Rabbani-Haghighi N, Naghsh N, Mehrabani D. The protective effect of curcuma longa in thioacetamide-induced hepatic injury in rat. *Global J Pharmacol.* 2013;7:203-207.
- 3 Khajehahmadi Z, Mehraban D, Ashraf MJ, et al. Healing effect of conditioned media from bone marrow-derived stem cells in thioacetamide-induced liver fibrosis of rat. *J Med Sci.* 2016;16:7-15. DOI:10.3923/jms.2016.7.15.
- 4 Mehrabani D, Khajehahmadi Z, Tajik P, et al. The regenerative effect of bone marrow-derived mesenchymal stem cells in thioacetamide-induced liver fibrosis of rat. *Arch Razi Inst.* 2019;74:279-86. DOI:10.22092/ari.2018.110029.1120. PMID:31592593.
- 5 Lonardo A, Leoni S, Alswat KA, et al. History of nonalcoholic fatty liver disease. *Int J Mol Sci.* 2020;21:5888. DOI:10.3390/ijms21165888. PMID:32824337.
- 6 Mensink RP, Plat J, Schrauwen P. Diet and nonalcoholic fatty liver disease. *Curr Opin Lipidol.* 2008;19:25-9. DOI:10.1097/MOL.0b013e3282f382ea. PMID:18196983.
- 7 Taghavi SAR, Sedighi SH, Mehrabani D, et al. Hepatitis D in chronic active hepatitis b: prevalence, liver enzymes and histopathology-an epidemiological study in Shiraz, southern Iran, 2003-2004. *Hepat Mon.* 2008;8:248-51.
- 8 Browning JD, Szczepaniak LS, Dobbins R, et al. Prevalence of hepatic steatosis in an urban Population in the United States: impact of ethnicity. *Hepatology.* 2004;40:1387-95. DOI:10.1002/hep.20466. PMID:15565570.
- 9 Williams CD, Stengel J, Asike MI, et al. Prevalence of nonalcoholic fatty liver disease and nonalcoholic steatohepatitis among a largely middle-aged Population utilizing ultrasound and liver biopsy: a Prospective study. *Gastroenterology.* 2011;140:124-31. DOI:10.1053/j.gastro.2010.09.038. PMID:20858492.
- 10 Sotoudehmanesh R, Sotoudeh M, Ali-Asgari A, et al. Silent liver diseases in autopsies from forensic medicine of Tehran. *Arch Iran Med.* 2006;9:324-8. PMID:17061603.
- 11 Rabbani-Haghighi N, Mehrabani D. The protective effect of boiled coffee on liver enzymes AST, ALT, ALP and total bilirubin in rats treated with thioacetamide. *J Babol Univ Med Sci.* 2014;16:41-9.
- 12 An S, Jang E, Lee JH. Preclinical evidence of curcuma longa and its noncurcuminoid constituents against hepatobiliary diseases: A review. *Evid Based Complement Alternat Med.* 2020;2020:8761435. DOI:10.1155/2020/8761435. PMID:32802138.
- 13 Zargar A. Pharmaceutical plants. 8th ed. Tehran: Publication of Tehran University; 1993.p.90-4. (Persian)
- 14 Schafferman D, Beharav A, Shabelsky E, et al. Evaluation of Citrullus colocynthis, a desert Plant native in Israel, as a Potential source of edible oil. *J Arid Environ.* 1998;40:431-9. DOI:10.1006/jare.1998.0454.
- 15 Madari H, Jacobs RS. An analysis of cytotoxic botanical formulations used in the traditional medicine of ancient Persia as abortifacients. *J Nat Prod.* 2004;67:1204-10. DOI:10.1021/np049953r. PMID:15332833.
- 16 Khalil M, Mohamed G, Dallak M, et al. The effect of Citrullus colocynthis pulp extract on the liver of diabetic rats a light and scanning electron microscopic study. *Am J Biochem Biotechnol.* 2010;6:155-63. DOI:10.3844/ajbbsp.2010.155.163.
- 17 Dehghani F, Talaei-Khozani T, Mesbah F, et al. Toxic effects of hydroalcoholic extract of Citrullus colocynthis on Pregnant mice. *Iran J Vet Res.* 2008;9:42-5.
- 18 Lewis RJ, Irving N. Sax's dangerous Properties of industrial materials. *Van Nostrand Reinhold.* 1992.
- 19 Bruck R, Weiss S, Traister A, et al. Induced hypothyroidism accelerates the regression of liver fibrosis in rats. *J Gastroenterol Hepatol.* 2007;22:2189-94. DOI:10.1111/j.1440-1746.2006.04777.x. PMID:18031379.
- 20 Ranjbar T, Masoumi SJ. The effect of Stevia rebaudiana on nonalcoholic fatty liver disease (NAFLD): A review. *Int J Nutr Sci.* 2018;3:2-6.
- 21 Hsu YJ, Wang CY, Lee MC, et al. Hepatoprotection by traditional essence of ginseng against carbon tetrachloride-induced liver damage. *Nutrients.* 2020;12:3214. DOI:10.3390/nu12103214. PMID:33096694.
- 22 Gu X, Manautou JE. Molecular mechanisms underlying chemical liver injury. *Expert Rev Mol Med.* 2012;14:e4. DOI:10.1017/S1462399411002110. PMID:22306029.
- 23 Hoekstra L, Graaf W, Nibourg AA, et al. Physiological and biochemical basis of clinical liver function tests: A review. *Ann Surg.* 2013;257:27-36. DOI:10.1097/SLA.0b013e31825d5d47. PMID:22836216
- 24 Cichoż-Lach H, Michalak A. Oxidative stress



- as a crucial factor in liver diseases. *World J Gastroenterol.* 2014;20:8082-91. DOI:10.3748/wjg.v20.i25.8082. PMID:25009380.
- 25 Weber LWD, Boll M, Stampfl A. Hepatotoxicity and mechanism of action of haloalkanes: Carbon tetrachloride as a toxicological model. *Crit Rev Toxicol.* 2003;33:105-36. DOI:10.1080/713611034. PMID:12708612.
  - 26 Lombardi B, Ugazio G, Raick AN. Choline-deficiency fatty liver: Relation of plasma phospholipids to liver triglycerides. *Am J Physiol.* 1966;210:31-36. DOI:10.1152/ajplegacy.1966.210.1.31. PMID:5903142.
  - 27 Ullah H, Khan A, Baig MW, et al. Poncirin attenuates CCL4-induced liver injury through inhibition of oxidative stress and inflammatory cytokines in mice. *BMC Complement Med Ther.* 2020;20:115. DOI:10.1186/s12906-020-02906-7. PMID:32307011.
  - 28 Zhang X, Kuang G, Wan J, et al. Salidroside protects mice against CCl4-induced acute liver injury via down-regulating CYP2E1 expression and inhibiting NLRP3 inflammasome activation. *Int Immunopharmacol.* 2020;85:106662. DOI:10.1016/j.intimp.2020.106662. PMID:32544869.
  - 29 Pierce RA, Glaug MR, Greco RS, et al. Increased Procollagen mRNA levels in carbon tetrachloride-induced liver fibrosis in rats. *J Biol Chem.* 1987;262:1652-8. PMID:3805048.
  - 30 Domenicali M, Caraceni P, Giannone F, et al. A novel model of CCl4-induced cirrhosis with ascites in the mouse. *J Hepatol.* 2009;51:991-9. DOI:10.1016/j.jhep.2009.09.008. PMID:19853952.
  - 31 Basaranoglu M, Acbay O, Sonsuz A. A controlled trial of gemfibrozil in the treatment of Patients with nonalcoholic steatohepatitis. *J Hepatol.* 1999;31:384. DOI:10.1016/s0168-8278(99)80243-8. PMID:10453959.
  - 32 Kiyici M, Gulten M, Gurel S, et al. Ursodeoxycholic acid and atorvastatin in the treatment of nonalcoholic steatohepatitis. *Can J Gastroenterol Hepatol.* 2003;17:713-8. DOI:10.1155/2003/857869. PMID:14679419.
  - 33 Daradka H, Almasad MM, Qazan WS, et al. Hypolipidaemic effects of Citrullus colocynthis L. in rabbits. *Pak J Biol Sci.* 2007;10:2768-71. DOI:10.3923/pjbs.2007.2768.2771. PMID:19070101.
  - 34 Atole S, Jangde C, Philip P, et al. Safety Evaluation Studies of Citrullus Colocynthis for diabetes in Rats. *Vet World.* 2009;2.
  - 35 Dehghani F, Panjehshahin MR. The toxic effect of alcoholic extract of Citrullus colocynthis on rat liver. *Iran Pharmacol Ther.* 2006;5:117-19.
  - 36 Naik SR, Panda VS. Antioxidant and hepatoprotective effects of Ginkgo biloba phytosomes in carbon tetrachloride-induced liver injury in rodents. *Liver Int.* 2007;27:393-9. DOI:10.1111/j.1478-3231.2007.01463.x. PMID:17355462.